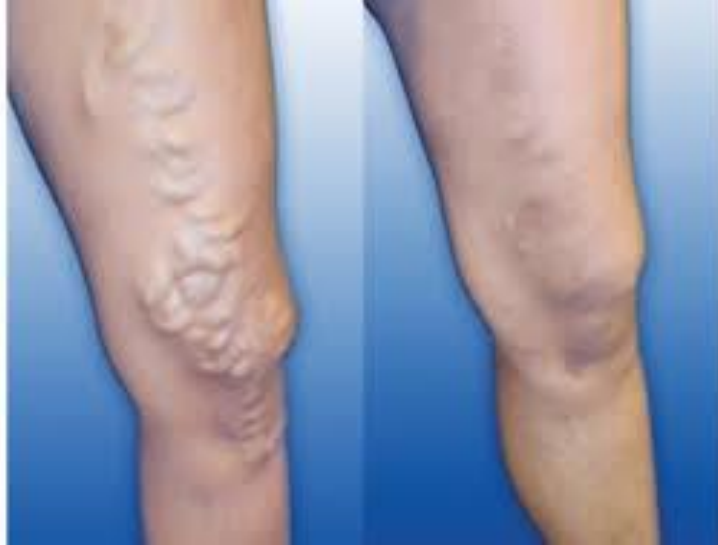



Lower Limb Venous Disease and Lymphoedema

Mr Mark E. O'Donnell

Consultant Vascular and Endovascular Surgeon

**DipSEM(GB&I) MFSEM(UK) MFSEM(RCSI&RCPI) MFSTEd MMedSc(Dist) MD
ECFMG RPVI(ARDMS) FRCSEd(Gen&Vasc Surg) FEBVS(Hon)**

Cumbria and Lancashire Vascular and Endovascular Centre

ASiT MRCS Part B (OSCE) Course – 7th September 2016

Safe | Personal | Effective



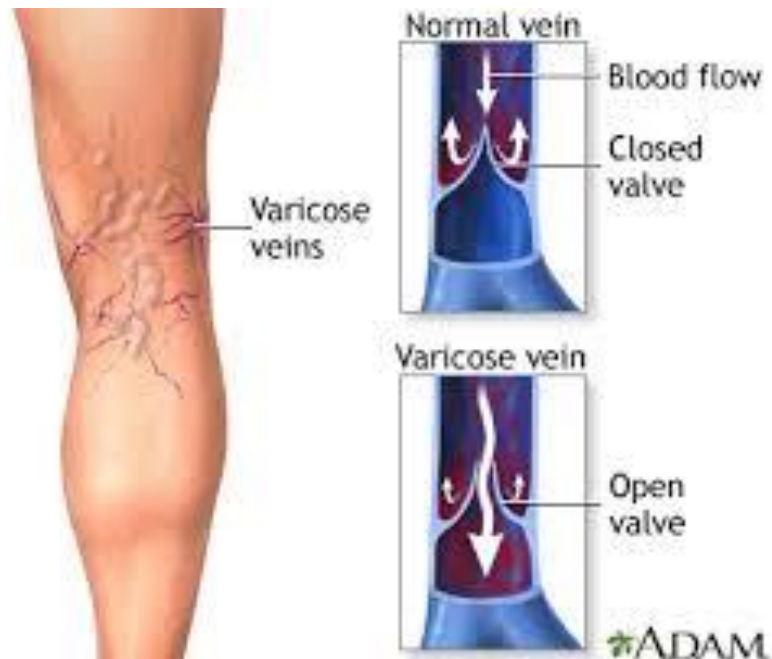
Learning Outcomes

- Background – Why treat?
- Therapeutic Strategies and Treatment Options.
- Operative / Endovenous Technique.
- Clinical Outcomes.
- Current Research.



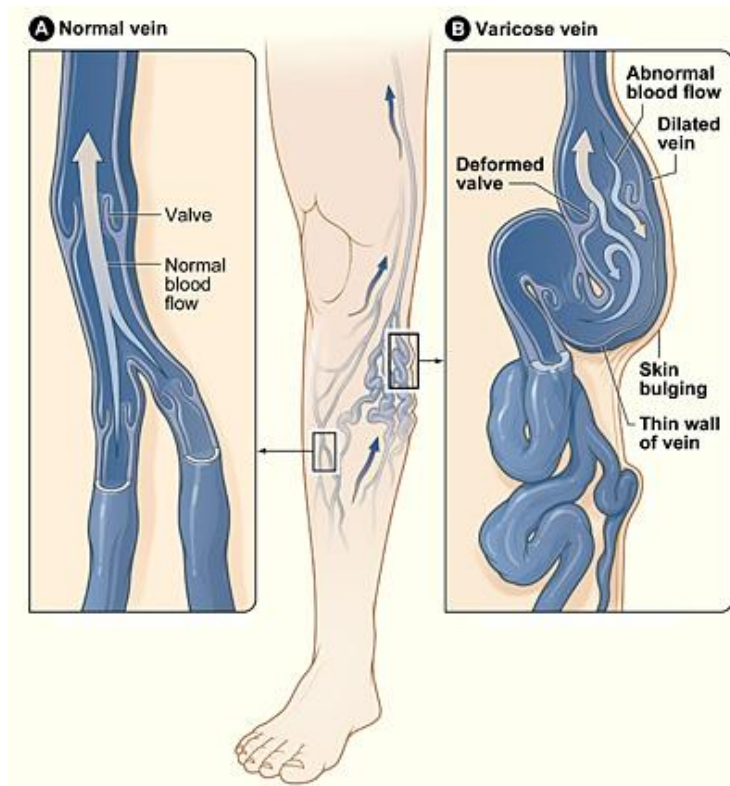
Definition

- Dilated, superficial, tortuous veins classically affecting the lower extremities.



Definition

- Dilated, superficial, tortuous veins classically affecting the lower extremities.



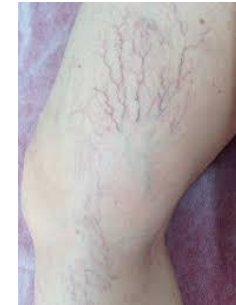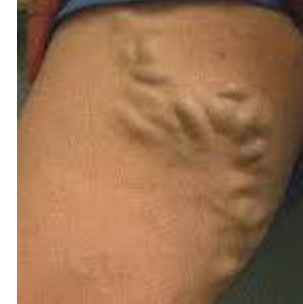Epidemiology

- Present in 25-40% of the population.
- Increased in developed countries.
- Males = females.
- Skin changes 5-10%.
- Chronic venous ulceration 0.3-1.0%.



Epidemiology

- Truncal veins very common;
 - Males 40% vs. females 32% .
- Mild varices – reticular / thread veins;
 - 80% of 18-64 years olds.
- Increases with age;
 - 15% of people between 25 and 34 years.
 - 50-60% of people between 55 and 64 years.



Aetiology

- Varicose veins are due to weakness in the wall of superficial veins which leads to stretching.
- The stretching causes failure of the one-way valves inside the veins. These valves normally only allow the blood to flow up the leg towards the heart.
- If the valves leak, then blood can flow back the wrong way when standing. This reverse flow (venous reflux) causes increased pressure on the veins, which bulge and become varicose.
- They may also be caused by occupations that require prolonged standing or weight bearing which increase pressure on the leg veins.
- They often appear during pregnancy and have a family history.



Aetiology

- Primary;
 - Occur in the absence of any underlying cause.
 - Risk factors – pregnancy, weight, posture and bowel habit.
 - Genetics – family history but no genetic link as yet.

- Secondary;
 - Occur as a consequence of another condition.
 - Congenital abnormalities.
 - Post-DVT.
 - Pelvic masses / tumours.
 - Valve abnormalities or venous outflow obstructions.



Clinical Features

- Most patients are symptomatic.
- Majority of patients consult for cosmetic reasons.
- Symptoms include;
 - Pain.
 - Swelling / heaviness.
 - Itch.
 - Burning / restlessness.
 - Cramps.



Clinical Features

- Most patients are symptomatic.
- Majority of patients consult for cosmetic reasons.
- Symptoms include;
 - Pain.
 - Swelling / heaviness.
 - Itch.
 - Burning / restlessness.
 - Cramps.
 - Inflammation.
 - Venous hypertension / ulcers.
 - Bleeding.

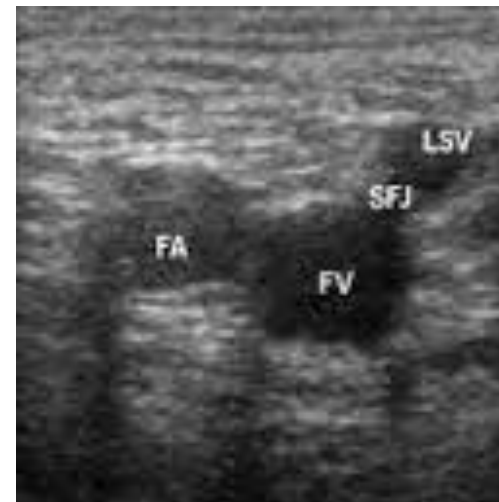
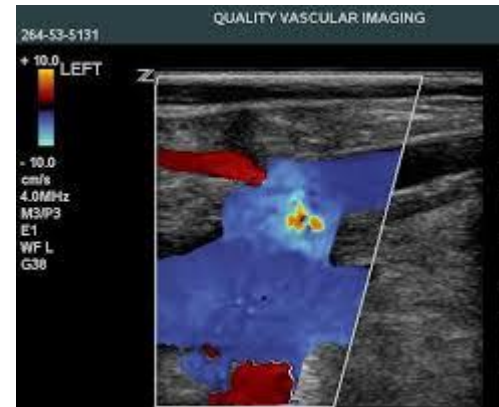
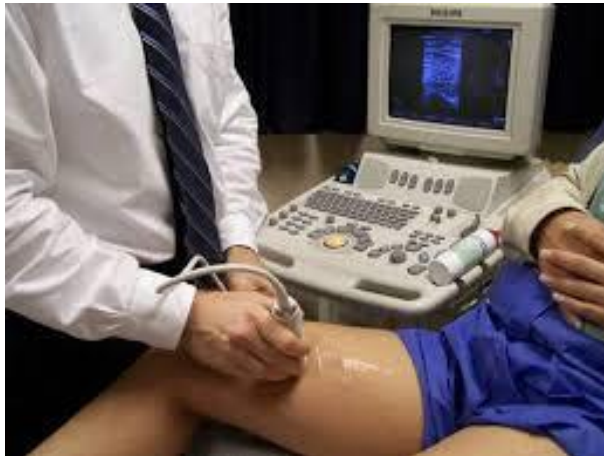

Clinical Assessment

- Inspection.
- Palpation.
- Tests;
 - Cough.
 - Tap.
 - Trendelenberg.
 - Tourniquet.
 - Perthes.
- Doppler.



Venous Duplex



Clinical*

- C₀ - No clinical signs
- C₁ - Small varicose veins
- C₂ - Large varicose veins
- C₃ - Edema
- C₄ - Skin changes without ulceration
- C₅ - Skin changes with healed ulceration
- C₆ - Skin changes with active ulceration

Etiology*

- E_C - Congenital
- E_P - Primary
- E_S - Secondary
(usually due to prior DVT)

Anatomy*

- A_S - Superficial veins
- A_D - Deep veins
- A_P - Perforating veins

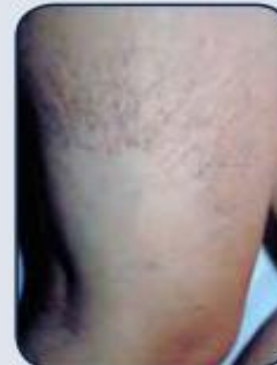Pathophysiology*

- P_R - Reflux
- P_O - Obstruction

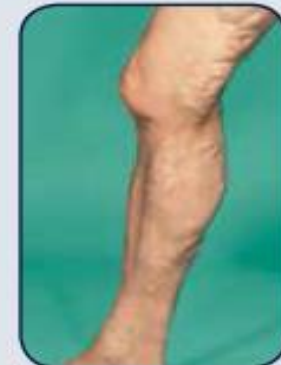"Early application of compression should be performed to correct swelling and progressive scarring and to initiate the healing process by improving the venous microcirculation."

Kistner R. Specific Steps to Effective Management of Venous Ulceration. Supplement to Wounds June 2010.

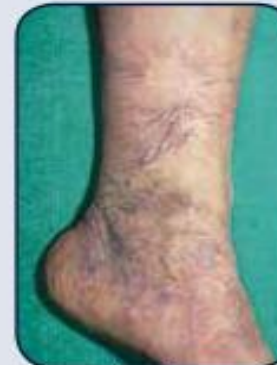Clinical Classifications with examples



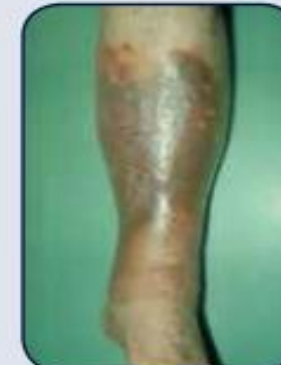C₁ - telangiectasias or reticular veins



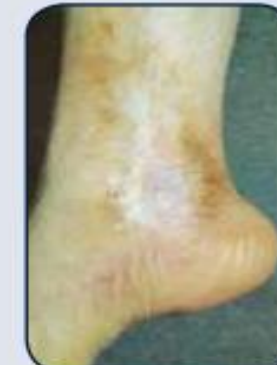C₂ - varicose veins



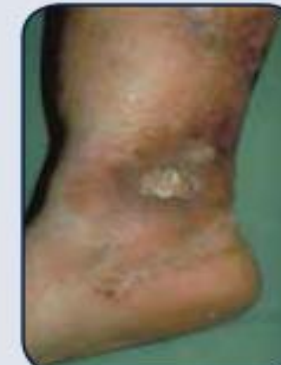C₃ - edema & corona



C₄ - lipodermatosclerosis and eczema



C₅ - ulcer scar



C₆ - active ulcer

International Consensus CEAP

Symptoms

Clinical signs

C0S

C1

C2

C3

C4

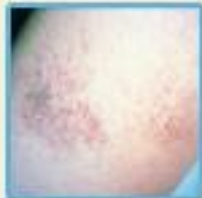C5

C6



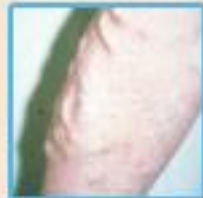Heavy legs, pains in the legs, pruritus...
But no clinical or palpable signs of venous disease

[▶ read more](#)



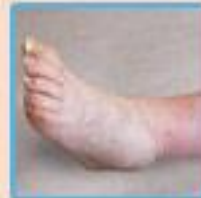Telangiectasia or reticular veins

[▶ read more](#)



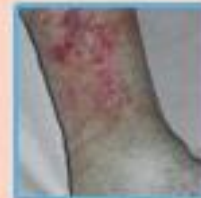Visible and palpable varicose veins

[▶ read more](#)



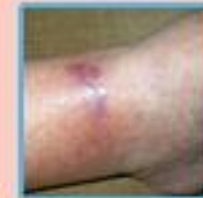Venous oedema (without trophic changes)

[▶ read more](#)



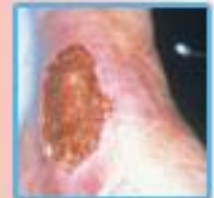Trophic changes of venous origin :
atrophie blanche,
pigmented purpuric dermatitis,
varicose eczema

[▶ read more](#)



healed ulcer with trophic changes

[▶ read more](#)



Presence of one or more active venous leg ulcers, often accompanied by trophic changes

[▶ read more](#)

C0 - C6 : description of the progression of the disease on the basis of the clinical signs present

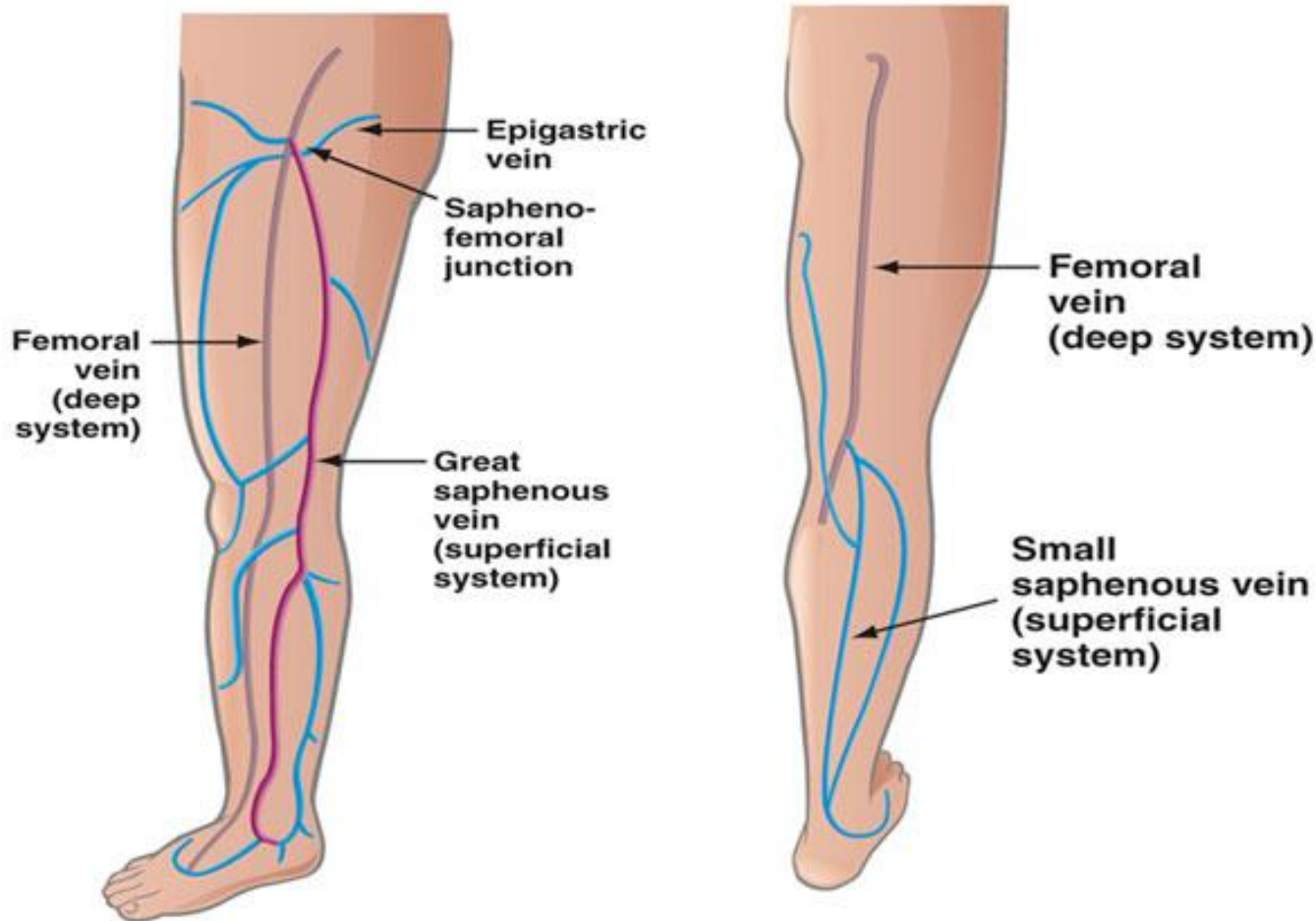
C : clinical signs

E : etiological classification

A : anatomical distribution

P : pathophysiological dysfunction

Anatomical Nomenclature



Why Treat – NICE Guidelines?

1.2 Referral to a vascular service

1.2.1 Refer people with bleeding varicose veins to a vascular service^[3] immediately.

1.2.2 Refer people to a vascular service if they have any of the following.

- Symptomatic^[4] primary or symptomatic recurrent varicose veins.
- Lower-limb skin changes, such as pigmentation or eczema, thought to be caused by chronic venous insufficiency.
- Superficial vein thrombosis (characterised by the appearance of hard, painful veins) and suspected venous incompetence.
- A venous leg ulcer (a break in the skin below the knee that has not healed within 2 weeks).
- A healed venous leg ulcer.

1.2 Referral to a vascular service



Why Treat – NICE Guidelines?

Interventional treatment

1.3.2 For people with confirmed varicose veins and truncal reflux:

- Offer endothermal ablation (see [Radiofrequency ablation of varicose veins](#) [NICE interventional procedure guidance 8] and [Endovenous laser treatment of the long saphenous vein](#) [NICE interventional procedure guidance 52]).
- If endothermal ablation is unsuitable, offer ultrasound-guided foam sclerotherapy (see [Ultrasound-guided foam sclerotherapy for varicose veins](#) [NICE interventional procedure guidance 440]).
- If ultrasound-guided foam sclerotherapy is unsuitable, offer surgery.

If incompetent varicose tributaries are to be treated, consider treating them at the same time.

Interventional treatment

1.3.3 If offering compression bandaging or hosiery for use after interventional treatment, do not use for more than 7 days.

Non-interventional treatment

1.3.4 Do not offer compression hosiery to treat varicose veins unless interventional treatment is unsuitable.



Why Treat – NICE Guidelines?

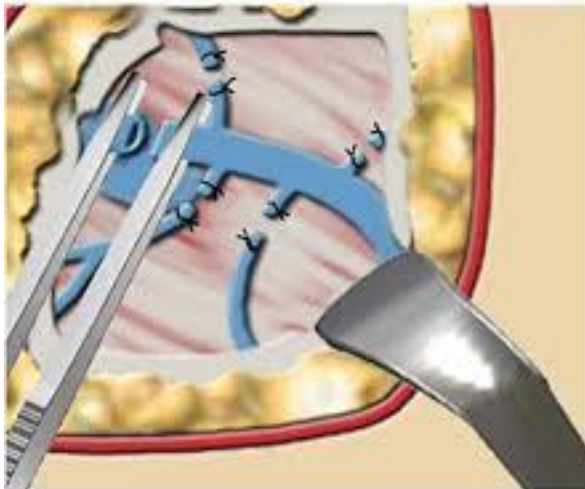
1.4 Management during pregnancy

- 1.4.1 Give pregnant women presenting with varicose veins information on the effect of pregnancy on varicose veins.
- 1.4.2 Do not carry out interventional treatment for varicose veins during pregnancy other than in exceptional circumstances.
- 1.4.3 Consider compression hosiery for symptom relief of leg swelling associated with varicose veins during pregnancy.

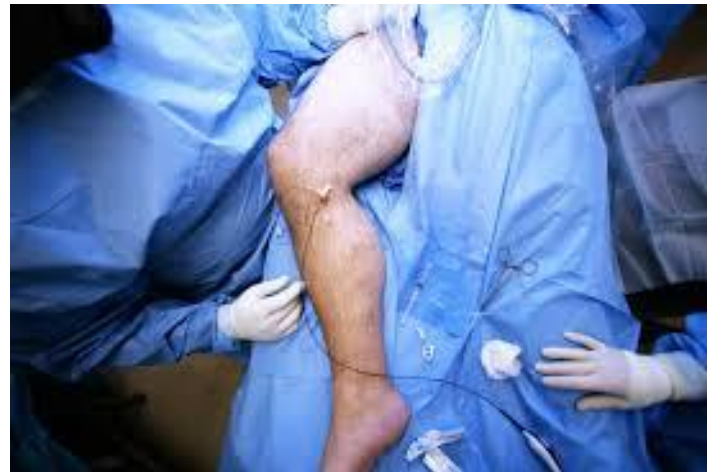

Treatment

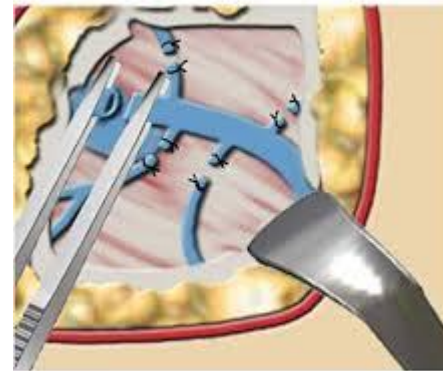
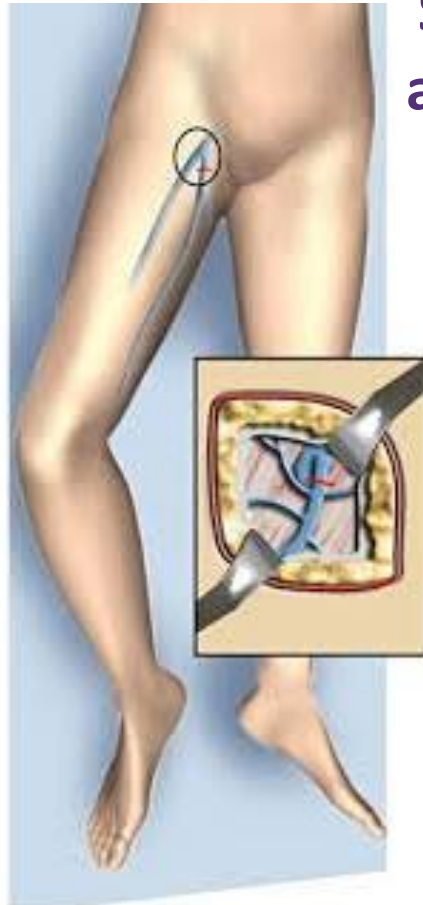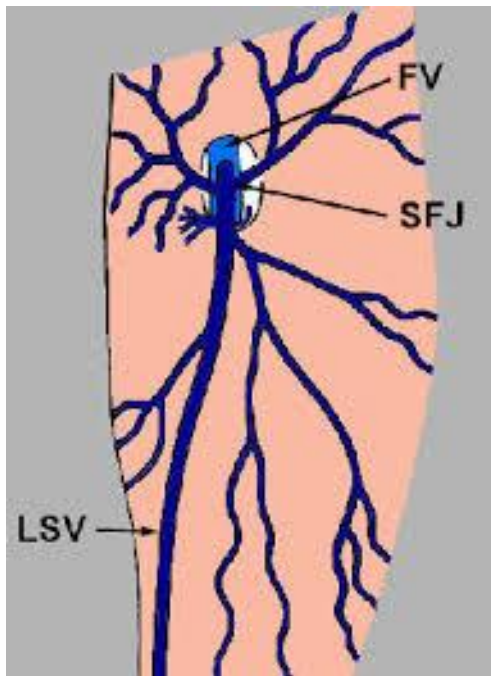
Traditional Surgery

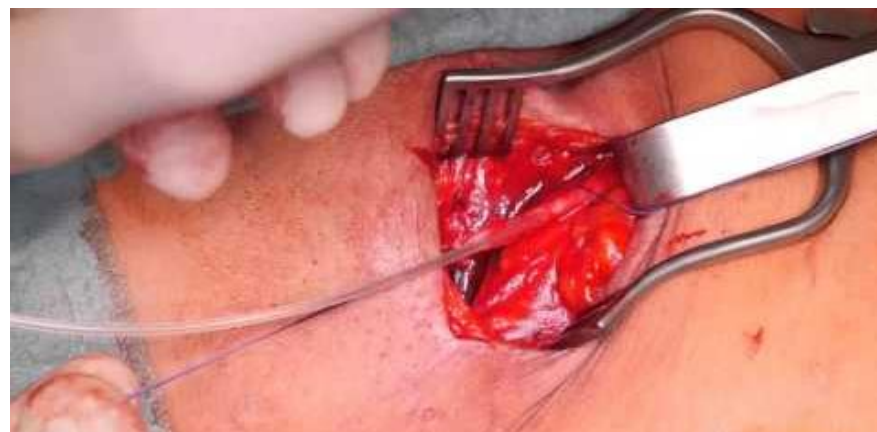
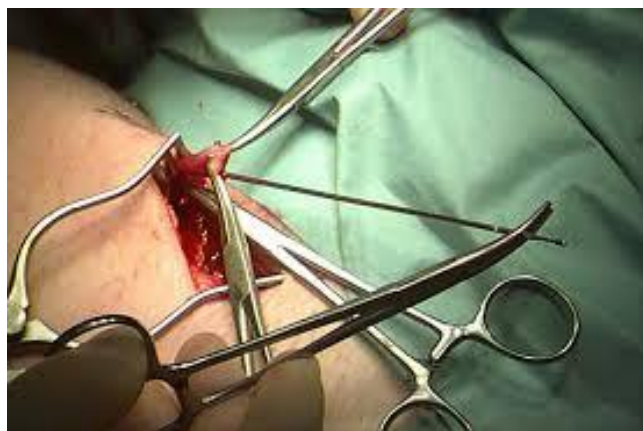
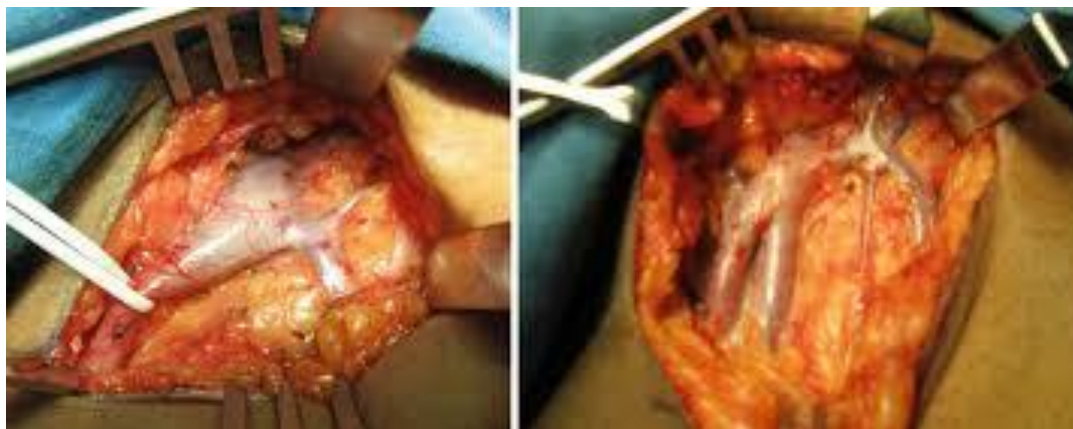Minimally Invasive



Traditional Open Surgery Sapheno-femoral junction ligation and great saphenous vein stripping





Recurrence rates between 15% and 20%

Safe | Personal | Effective



Endovenous Therapeutic Strategies

- Radiofrequency Ablation.
- Laser.
- Mechanical.
- Glue.
- Cryotherapy.
- Varicosity Adjuncts.

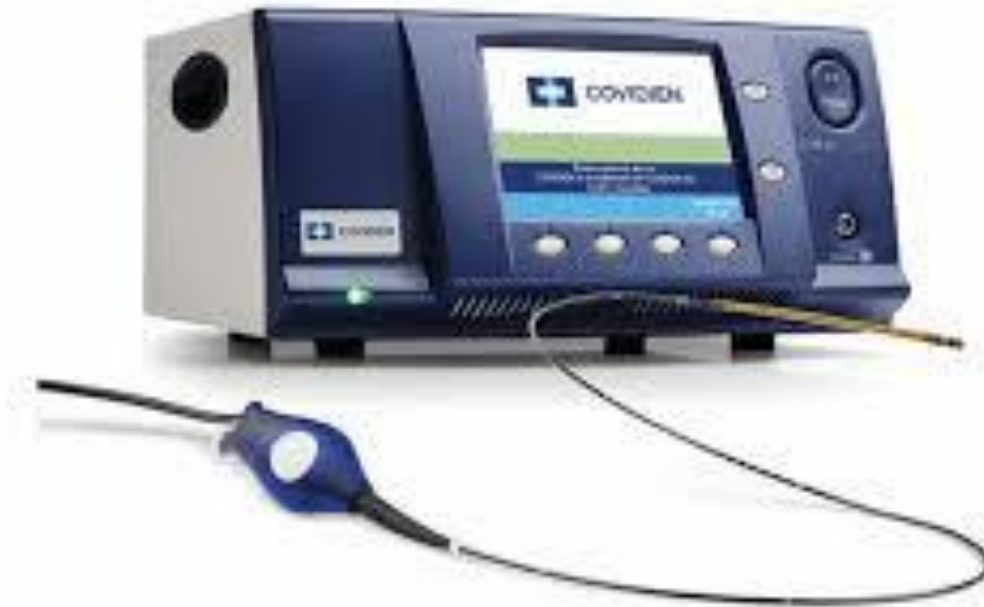

Therapeutic Strategies

- Radiofrequency Ablation.
- Laser.
- Mechanical.
- Glue.
- Cryotherapy.
- Varicosity Adjuncts.



Radio Frequency Ablation - Closurefast

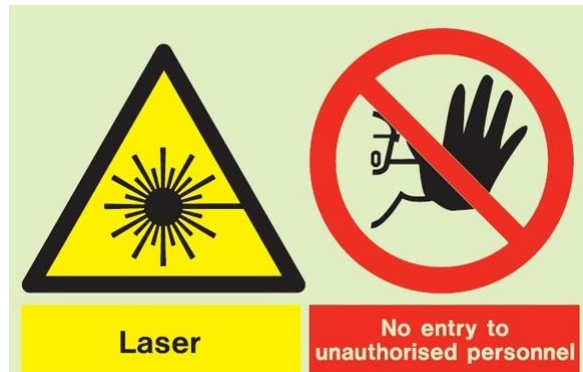
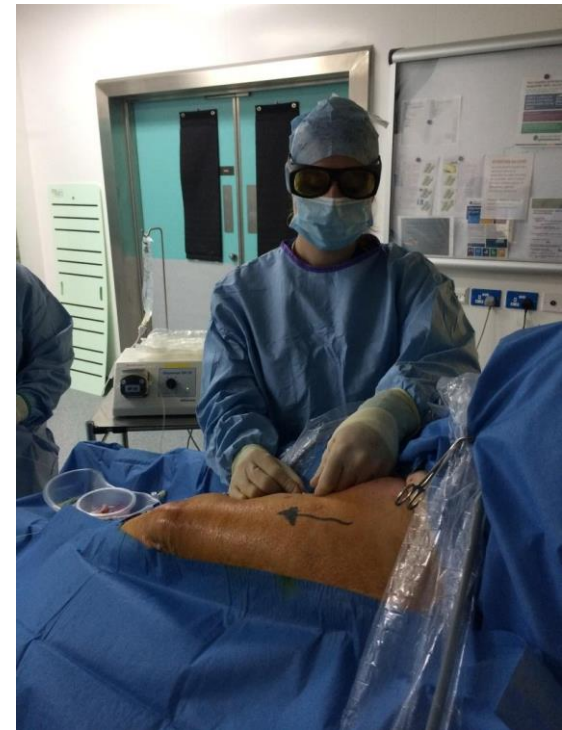
Therapeutic Strategies

- Radiofrequency Ablation.
- **Laser.**
- Mechanical.
- Glue.
- Cryotherapy.
- Varicosity Adjuncts.



Laser



Safe | Personal | Effective

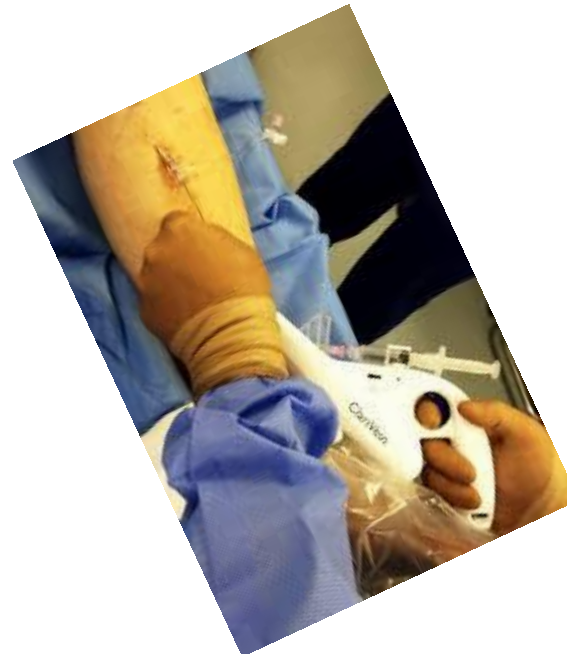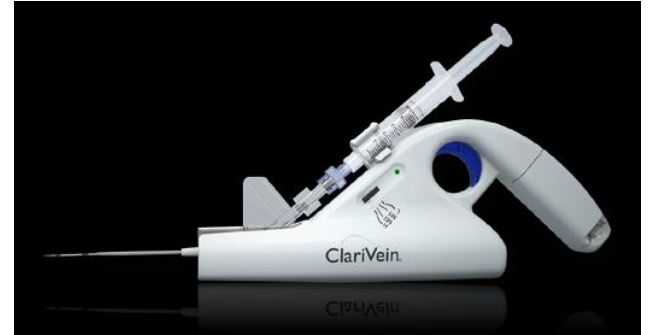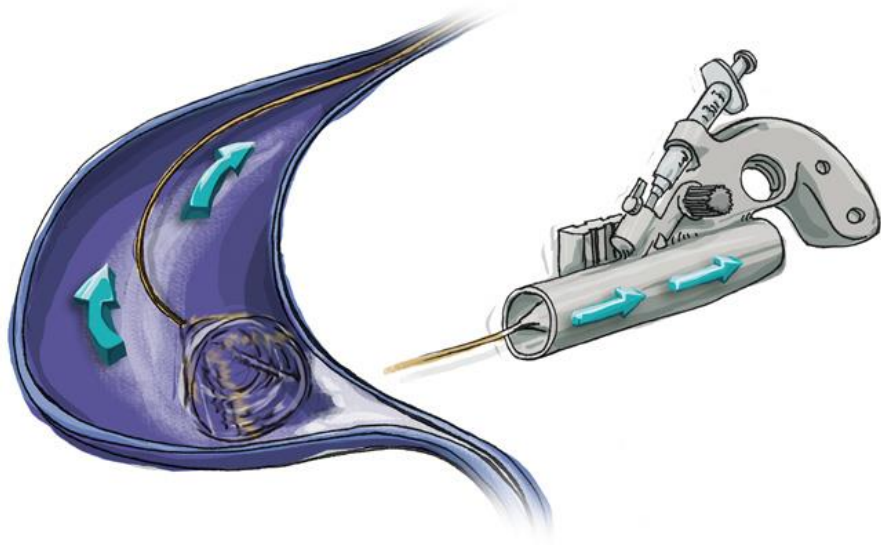


Therapeutic Strategies

- Radiofrequency Ablation.
- Laser.
- **Mechanical.**
- Glue.
- Cryotherapy.
- Varicosity Adjuncts.



Mechanical - Clarivein



Safe | Personal | Effective

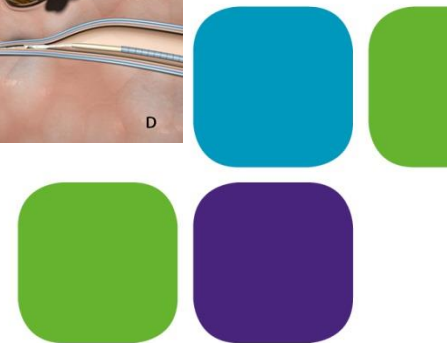
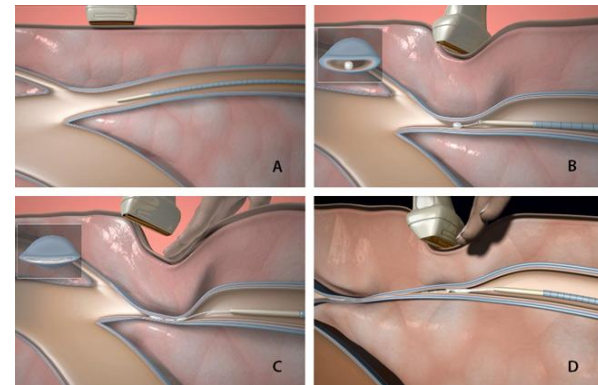
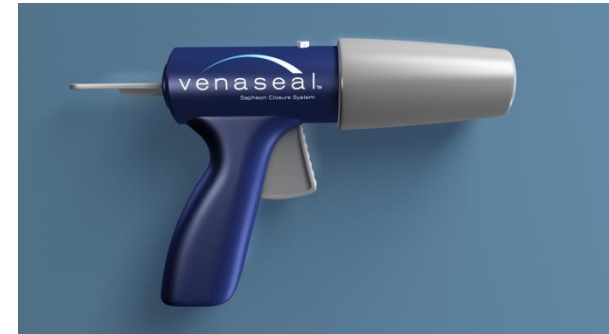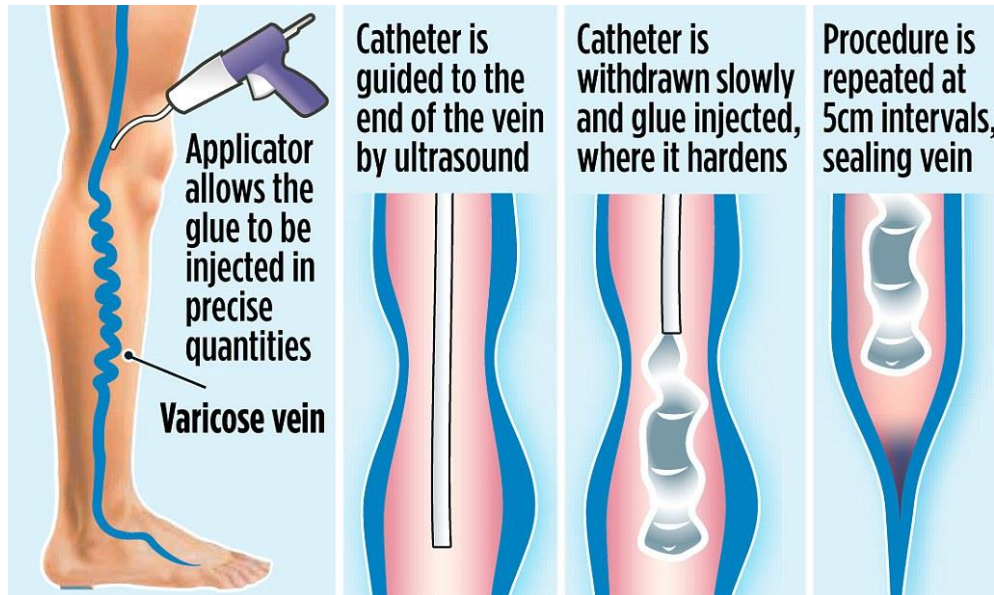


Therapeutic Strategies

- Radiofrequency Ablation.
- Laser.
- Mechanical.
- Glue.
- Cryotherapy.
- Varicosity Adjuncts.



Glue - Venaseal



Therapeutic Strategies

- Radiofrequency Ablation.
- Laser.
- Mechanical.
- Glue.
- Cryotherapy.
- Varicosity Adjuncts.



Cryotherapy



Safe | Personal | Effective

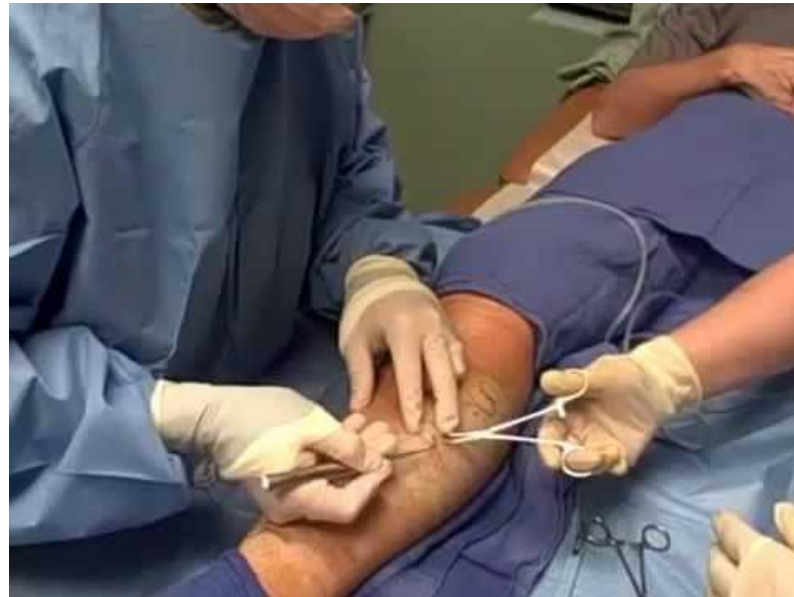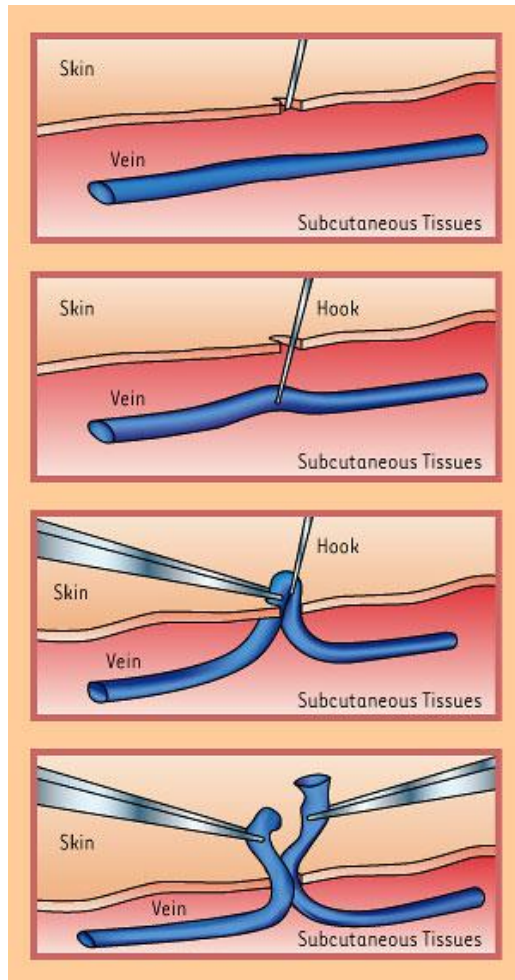


Therapeutic Strategies

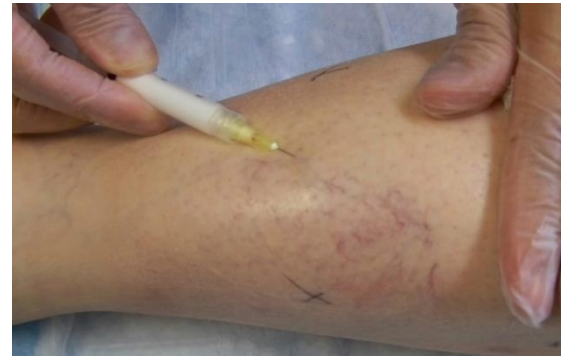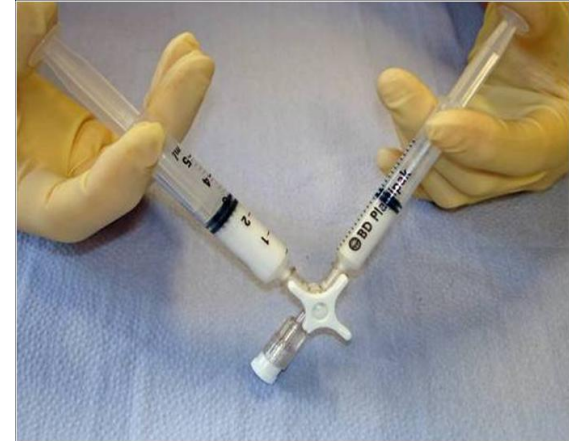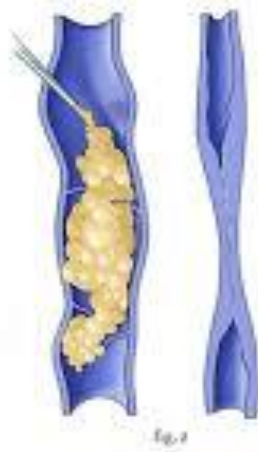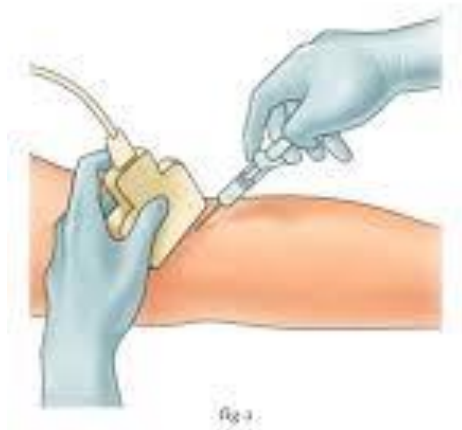- Radiofrequency Ablation.
- Laser.
- Mechanical.
- Glue.
- Cryotherapy.
- **Varicosity Adjuncts.**



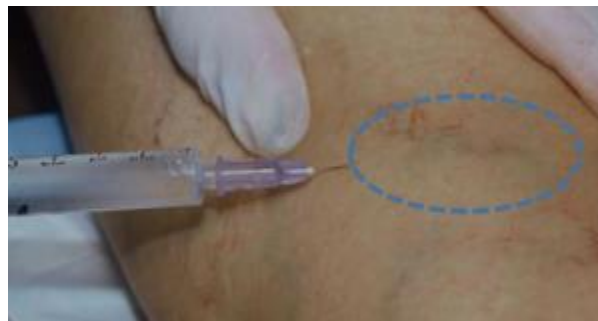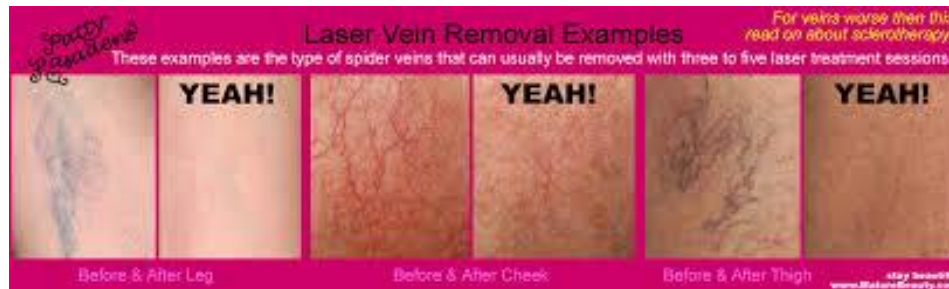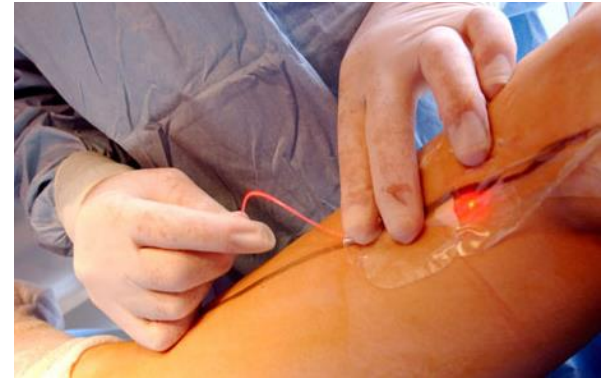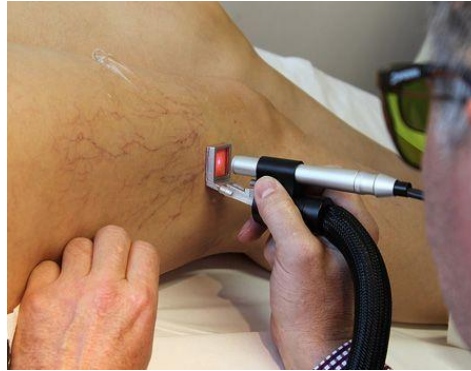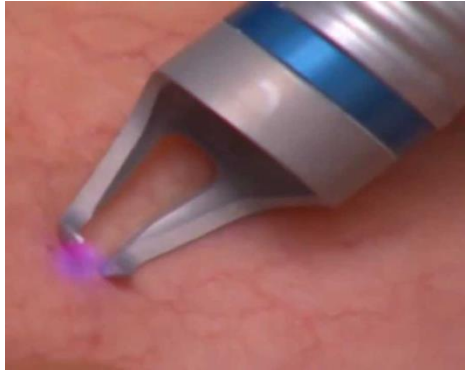Traditional Phlebectomy



Injection Sclerotherapy



Reticular / Thread Veins



Safe | Personal | Effective



Radio Frequency Ablation - Closurefast



Consent

- General Local Complications;
 - Pain, Bruising, Bleeding, Wound infection.
- Systemic Complications;
 - Cardiovascular, Respiratory, Thromboembolic.
- Procedural Specific Complications;
 - Scar.
 - Skin marking.
 - Thrombophlebitis.
 - Numbness / nerve injury.
 - Failure to improve symptoms.
 - Failure to remove all varicose veins.
 - Recurrence.
 - Further surgery.



Patient Preparation

- Normal operating table.
- Patient Position;
 - Supine for GSV.
 - Prone for SSV.
- No need for vein board.
- Shave phlebectomy sites.
- Generally local anaesthetic – add protocols.



Patient Preparation

- Normal operating table.
- Patient Position;
 - Supine for GSV.
 - Prone for SSV.
- No need for vein board.
- Shave phlebectomy sites.
- Generally local anaesthetic.
- **7cm RFA catheter unless specifically advised.**

Safe | Personal | Effective

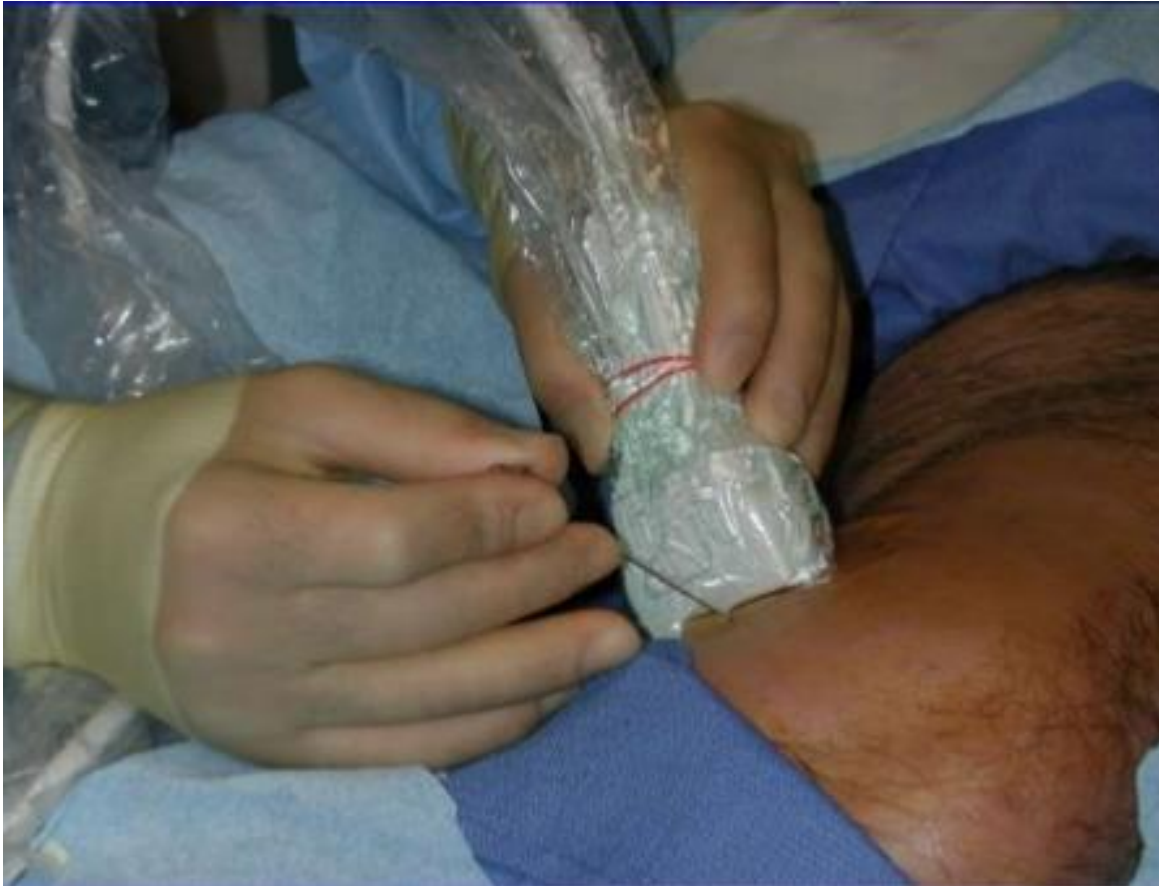

RFA – ClosureFast Treatment

- Aseptic preparation of lower limb.
- Ultrasound evaluation of GSV entry point.
- 5mls syringe with 1-2 mls saline with 19G needle.
- Ensure needle not too tightly affected to syringe.
- 1% lidocaine for GSV puncture.



1- Vein Puncture

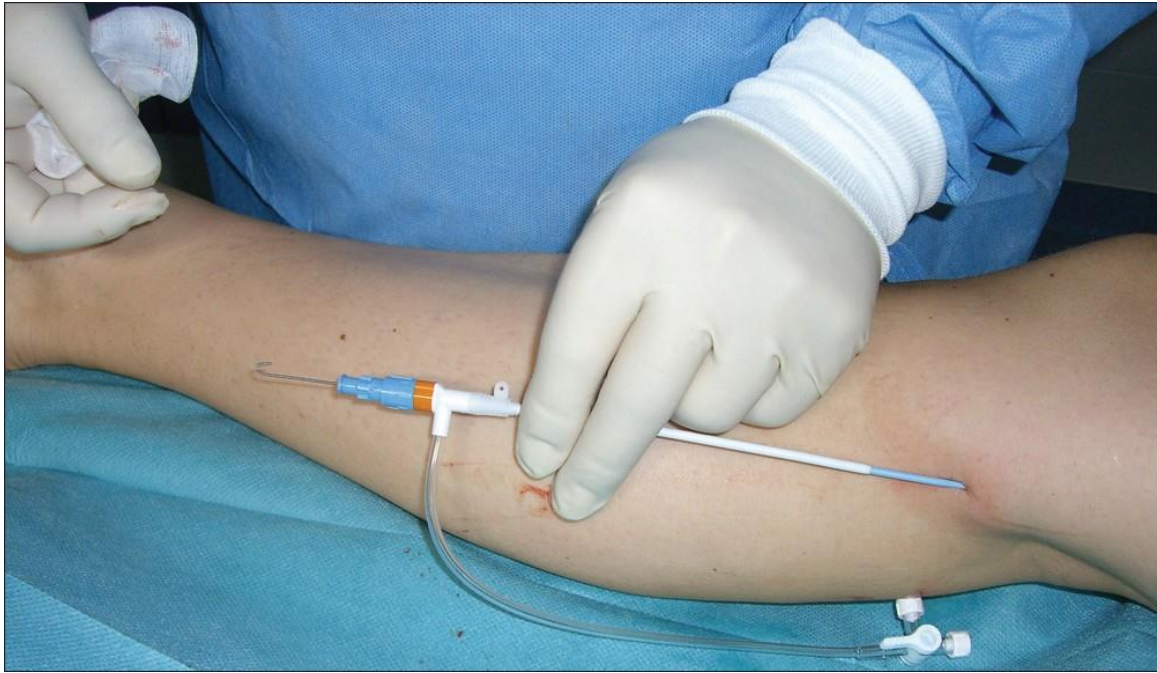


2 – Wire Insertion

- Vein accessed percutaneously and aspirating blood freely.
- Keep needle as still as possible and detach syringe.
- Insert wire – should have minimal resistance and pain for patient.
- Remove needle.
- Make a small vertical incision with scalpel.



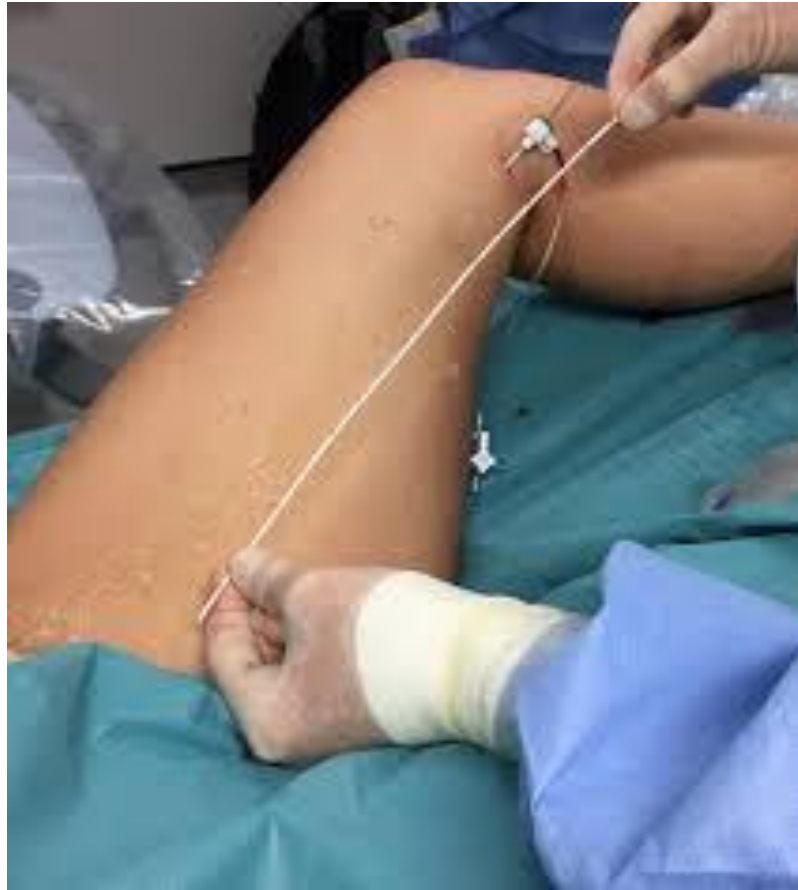3 – Sheath Insertion



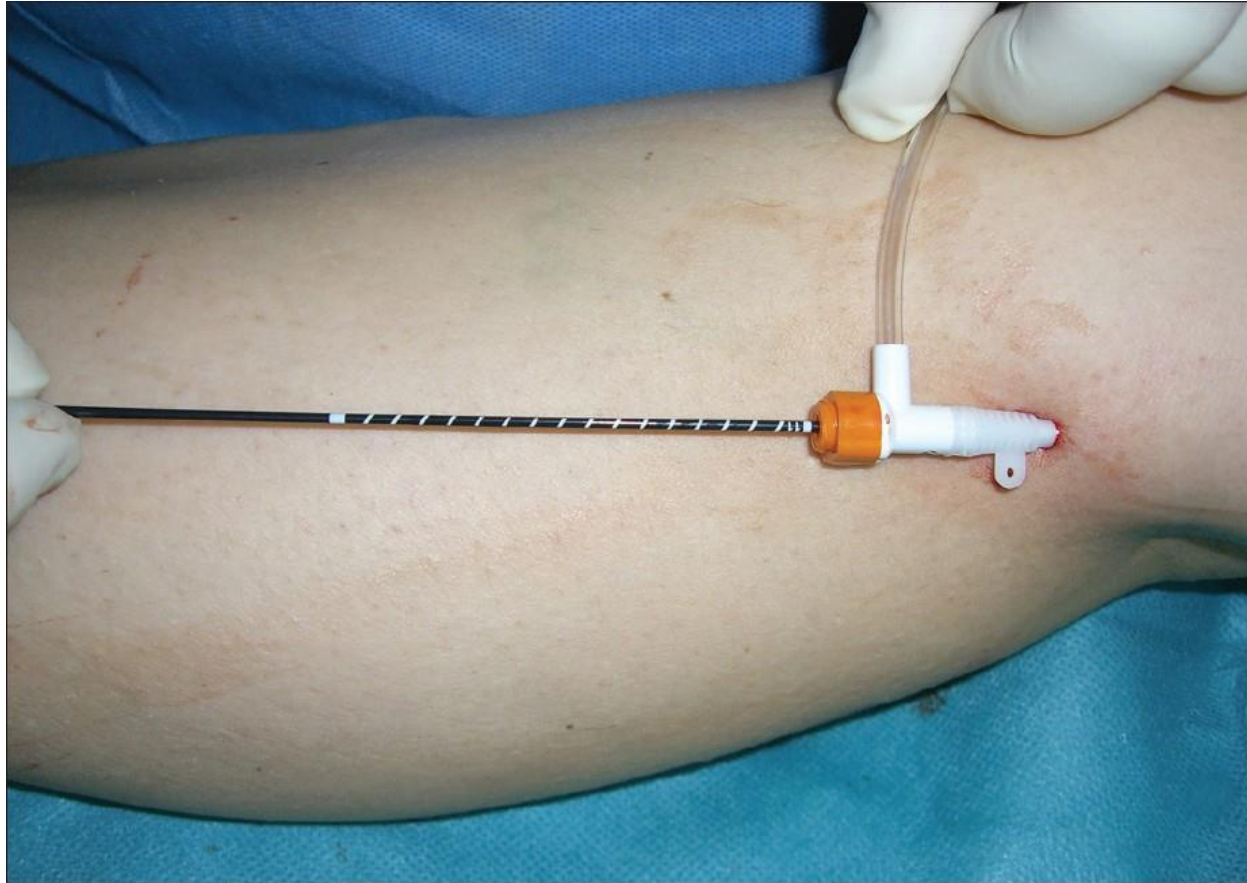
- 7Fr sheath inserted carefully holding wire;
 - Ensure sheath flushed.
 - Connect introducer properly.
 - Turn side taps off.



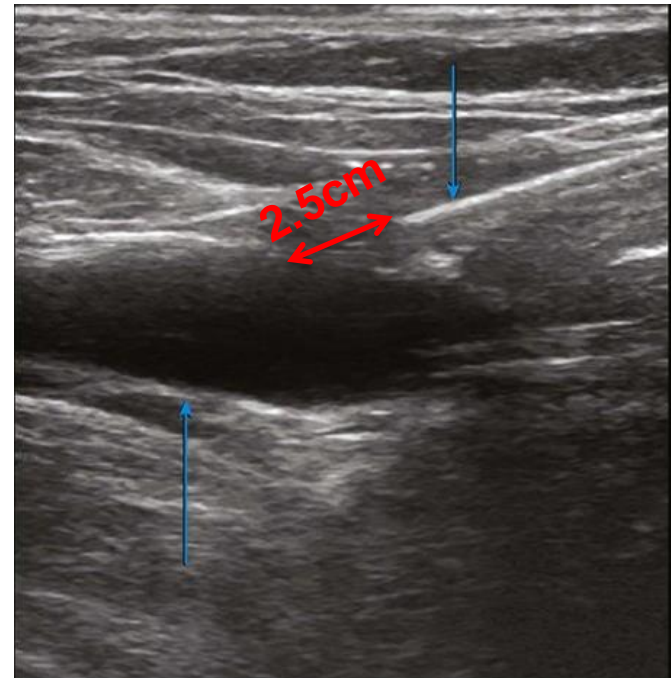
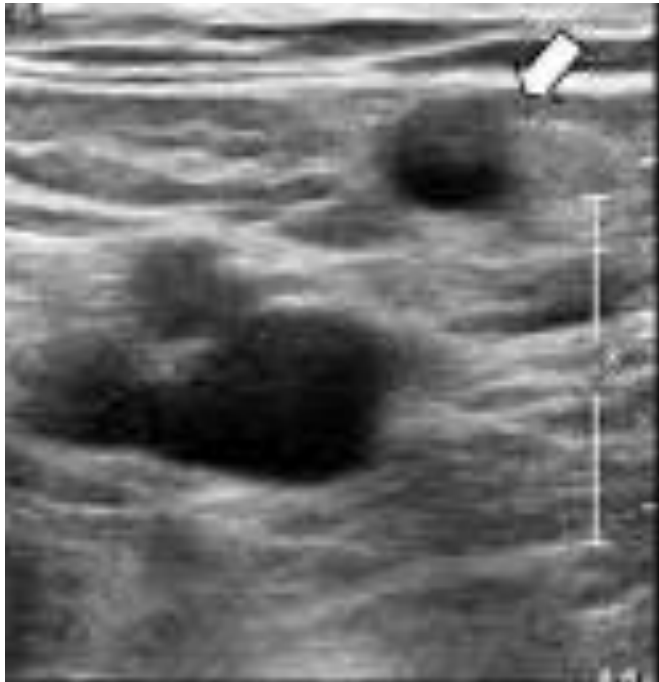4 – Measure distance to SFJ



5 – ClosureFast Catheter Insertion



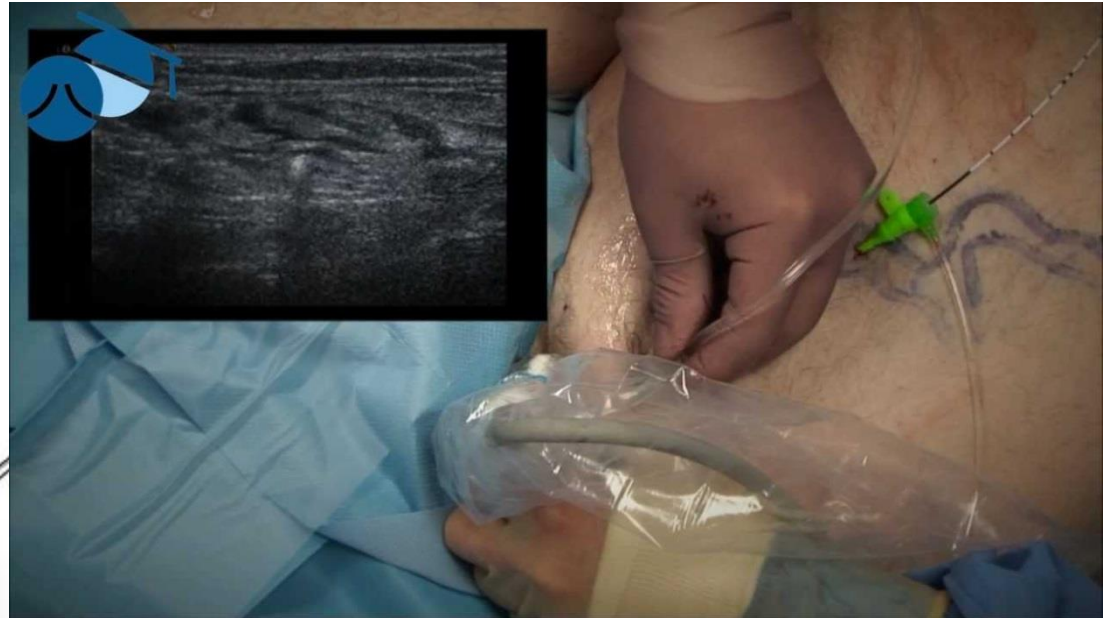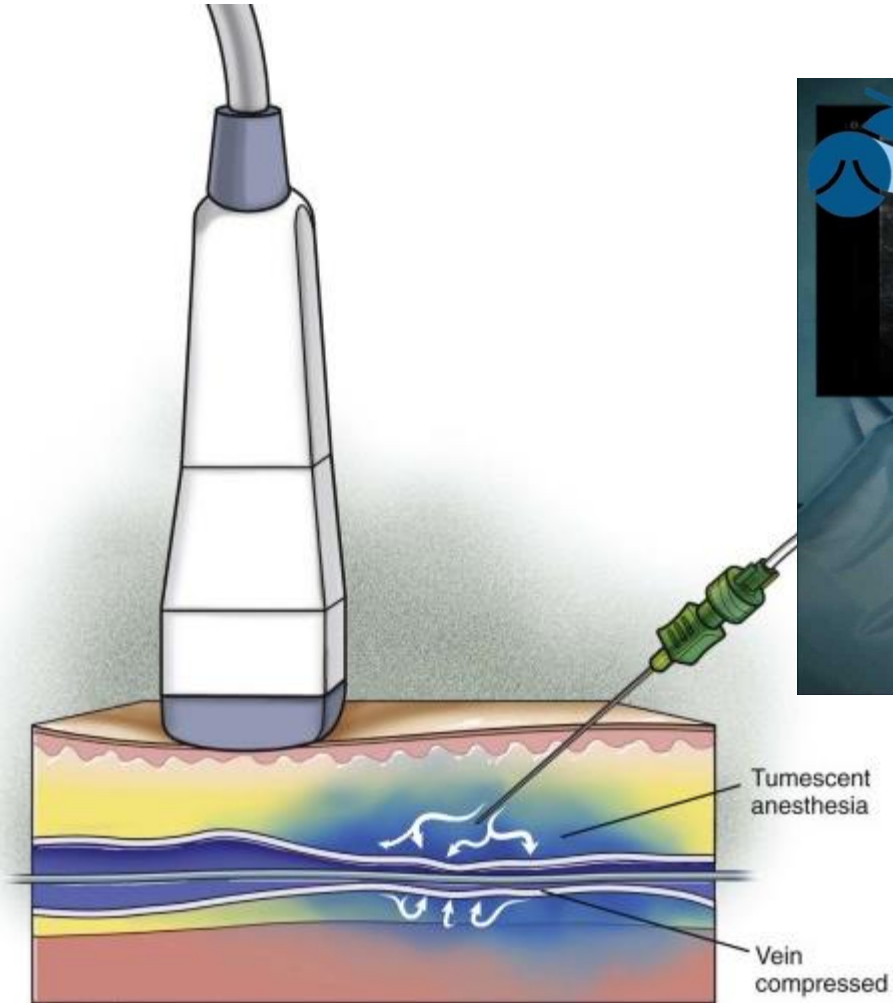
6 – Re-evaluate the SFJ



ClosureFast catheter placed 2.5cm distal to SFJ



7 – LA Tumescence

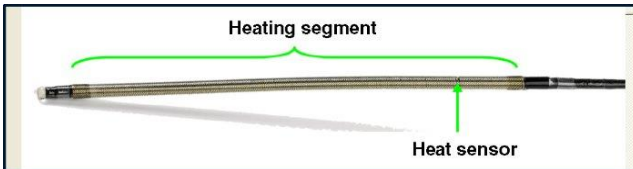
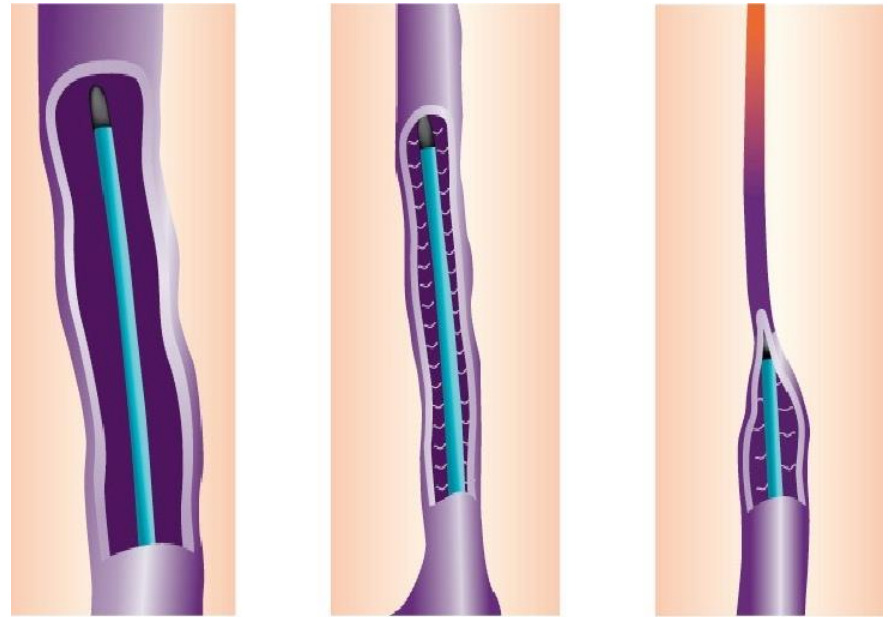
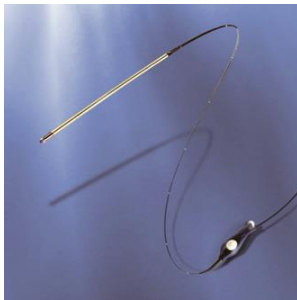

**50mls 1% Lidocaine +
Adrenaline in 500mls saline**

Safe | Personal | Effective



8 – RFA Treatment



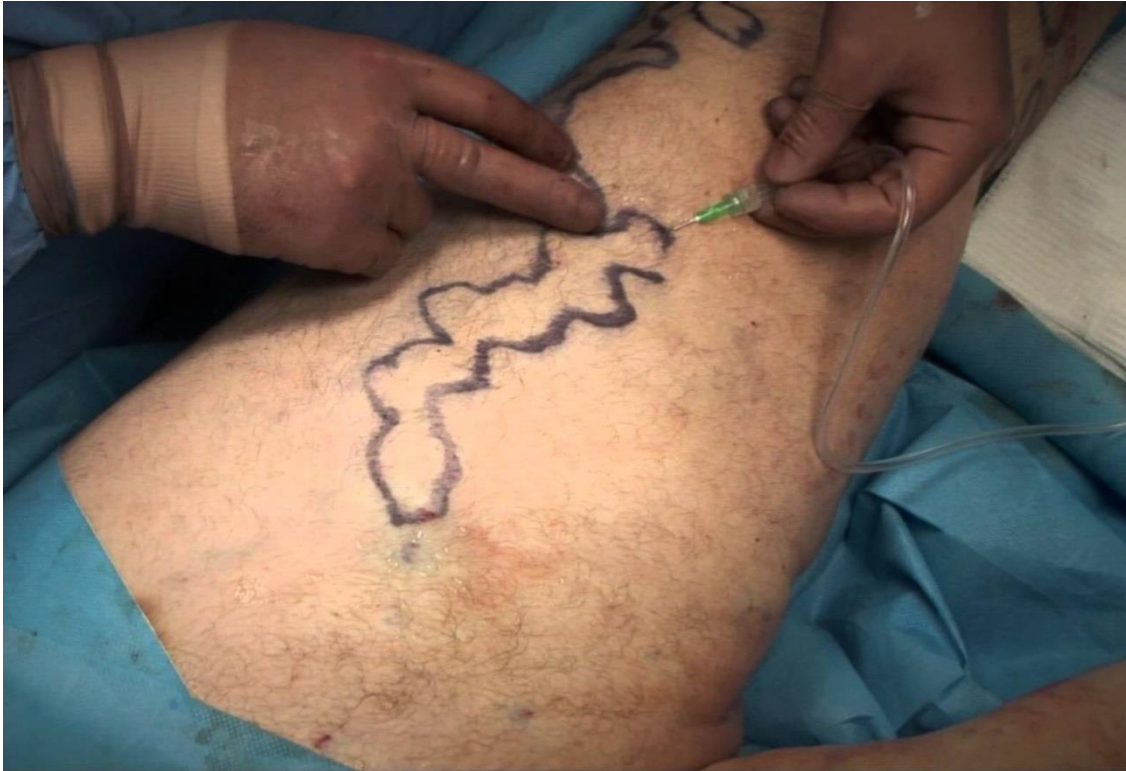Double treat first 7cm zone.

Record number of 20sec treatment cycles

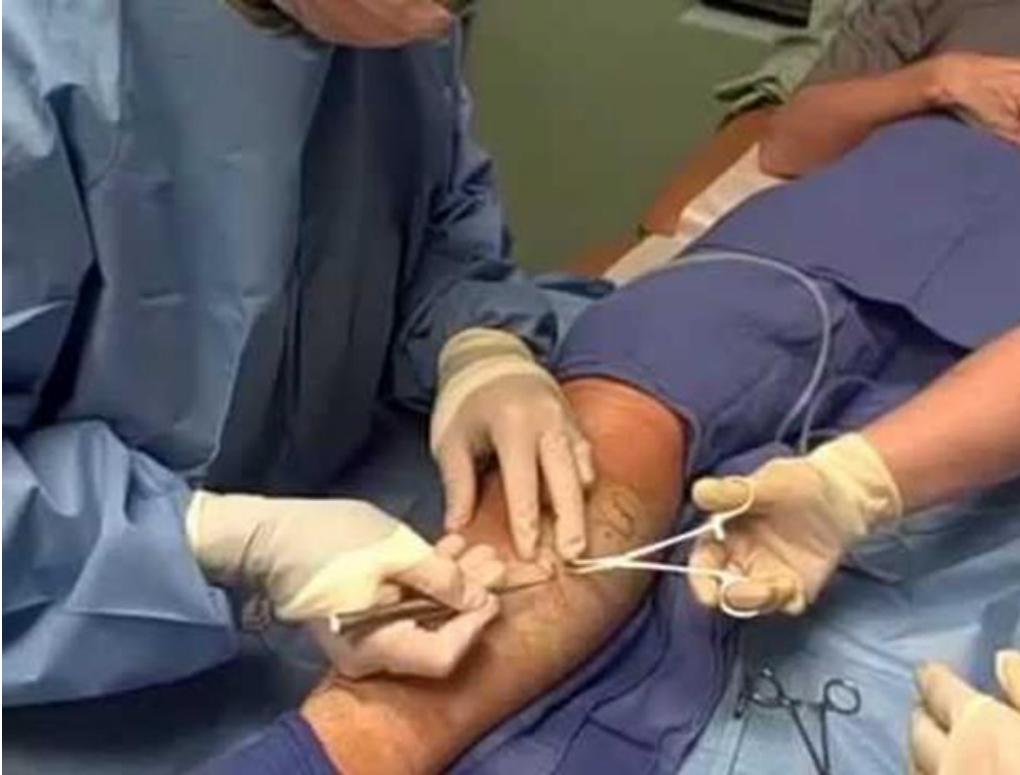Safe | Personal | Effective



9 – LA infiltration for phlebectomy



10 – Phlebectomy



Post-procedural care

- Lavage lower limb and dry.
- Steri-strips.
- Gauze / Wool / Crepe.
- Credilast compression hosiery.
- Day case discharge.
- Oral analgesia – 3pm and before bed.
- No OPD review.



Post-procedural care

- Lavage lower limb and dry.
- Steri-strips.
- Gauze / Wool / Crepe.
- Credilast compression hosiery.
- Day case discharge.
- Oral analgesia – 3pm and before bed.
- No OPD review.

Dressings
Remove 24-48
hours

Compression
1 week only



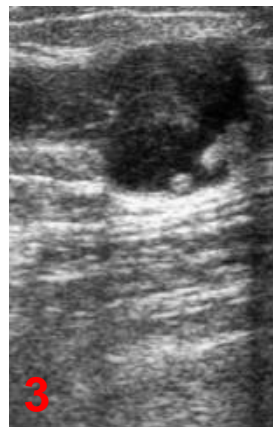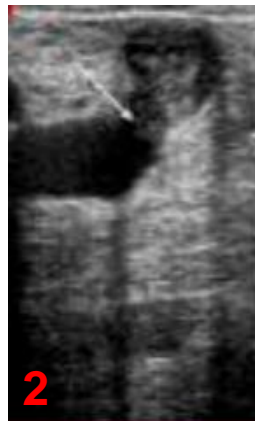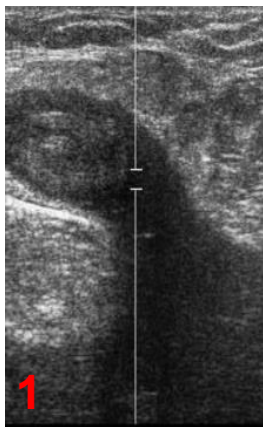Problems !!!

- Cannot stick vessel;
 - Warm room.
 - Elevate head.
 - More proximal puncture site.
- Cannot progress wire;
 - Bend straighten lower limb.
 - Massage area of difficulty under US guidance. I
- Painful procedure;
 - Stop immediately – more LA.



Complications

- Bleeding.
- Thrombophlebitis.
- Cellulitis.
- Endovenous Heat Induced Thrombosis – EHIT.

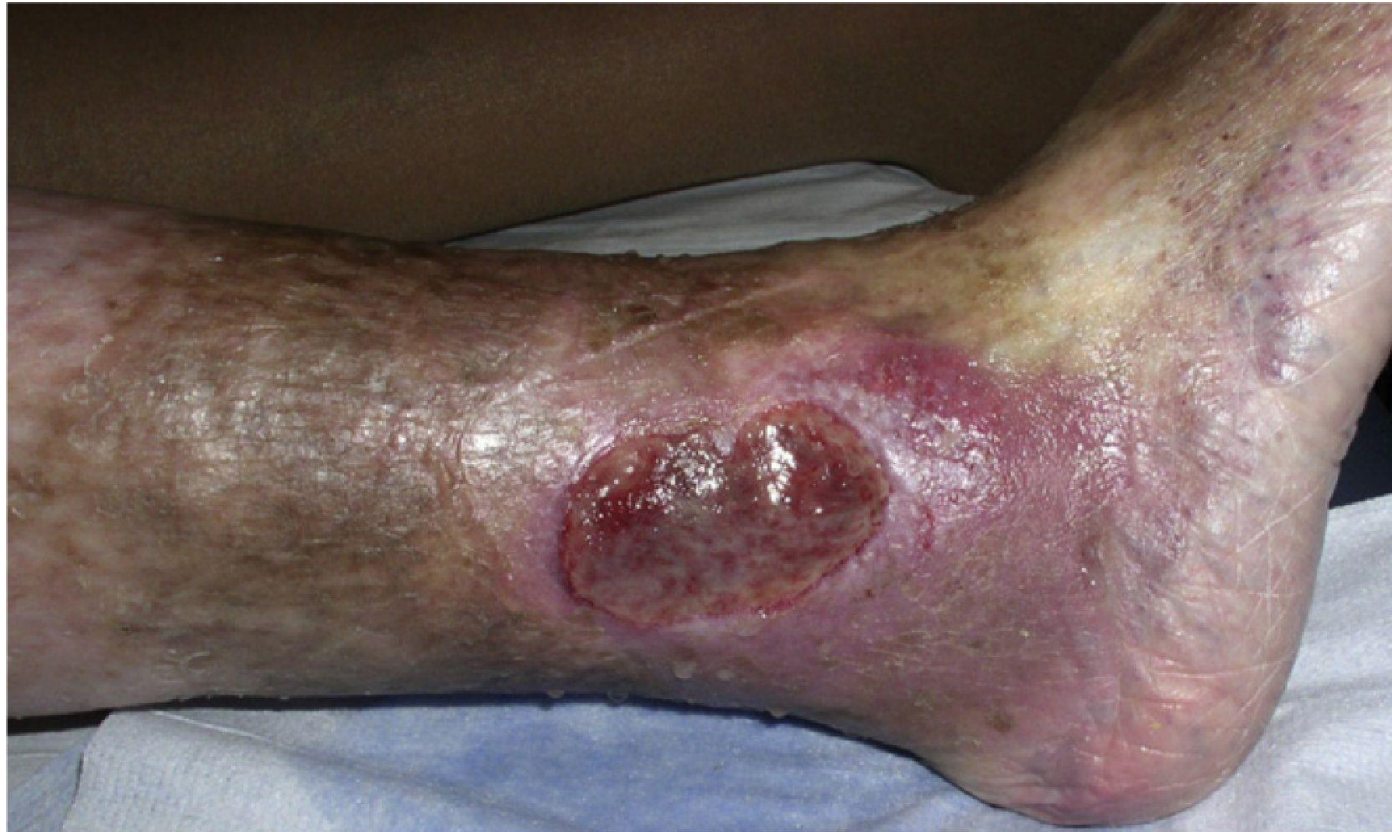


Complete
Occlusion



Safe | Personal | Effective

Venous Ulcers



Clinical*

- C₀ - No clinical signs
- C₁ - Small varicose veins
- C₂ - Large varicose veins
- C₃ - Edema
- C₄ - Skin changes without ulceration
- C₅ - Skin changes with healed ulceration
- C₆ - Skin changes with active ulceration

Etiology*

- E_C - Congenital
- E_P - Primary
- E_S - Secondary
(usually due to prior DVT)

Anatomy*

- A_S - Superficial veins
- A_D - Deep veins
- A_P - Perforating veins

Pathophysiology*

- P_R - Reflux
- P_O - Obstruction

"Early application of compression should be performed to correct swelling and progressive scarring and to initiate the healing process by improving the venous microcirculation."

Kistner R. Specific Steps to Effective Management of Venous Ulceration. Supplement to Wounds June 2010.

Clinical Classifications with examples



C₁ - telangiectasias or reticular veins



C₂ - varicose veins



C₃ - edema & corona



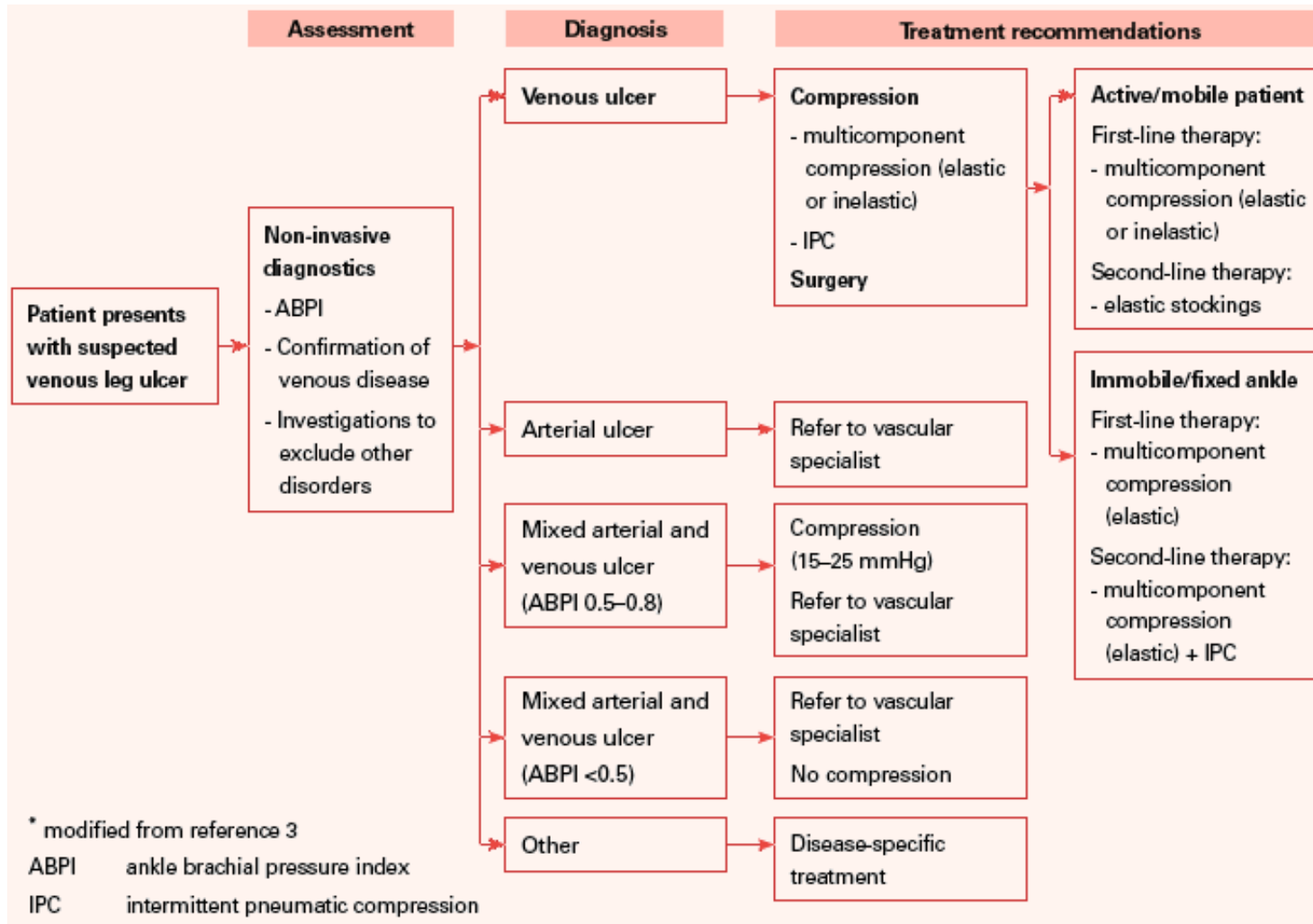
C₄ - lipodermatosclerosis and eczema



C₅ - ulcer scar



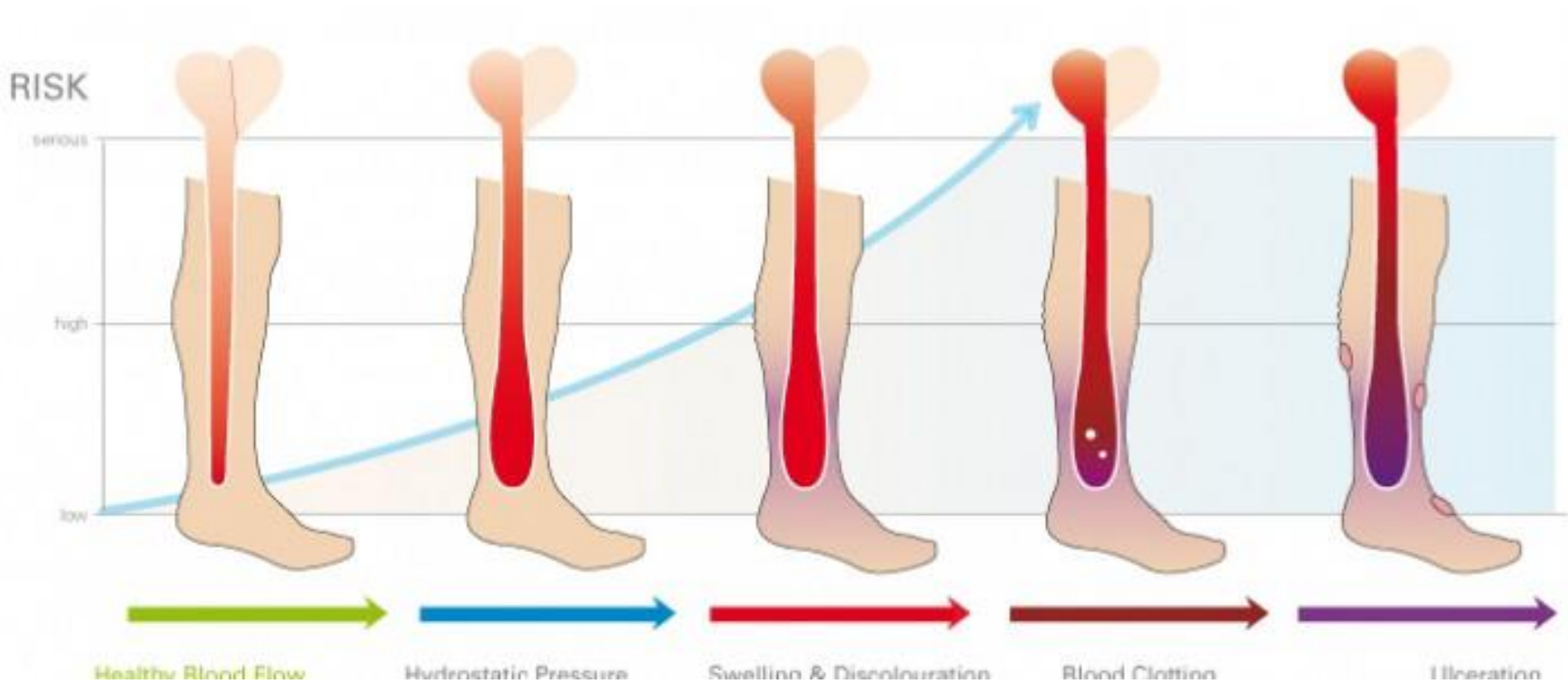
C₆ - active ulcer



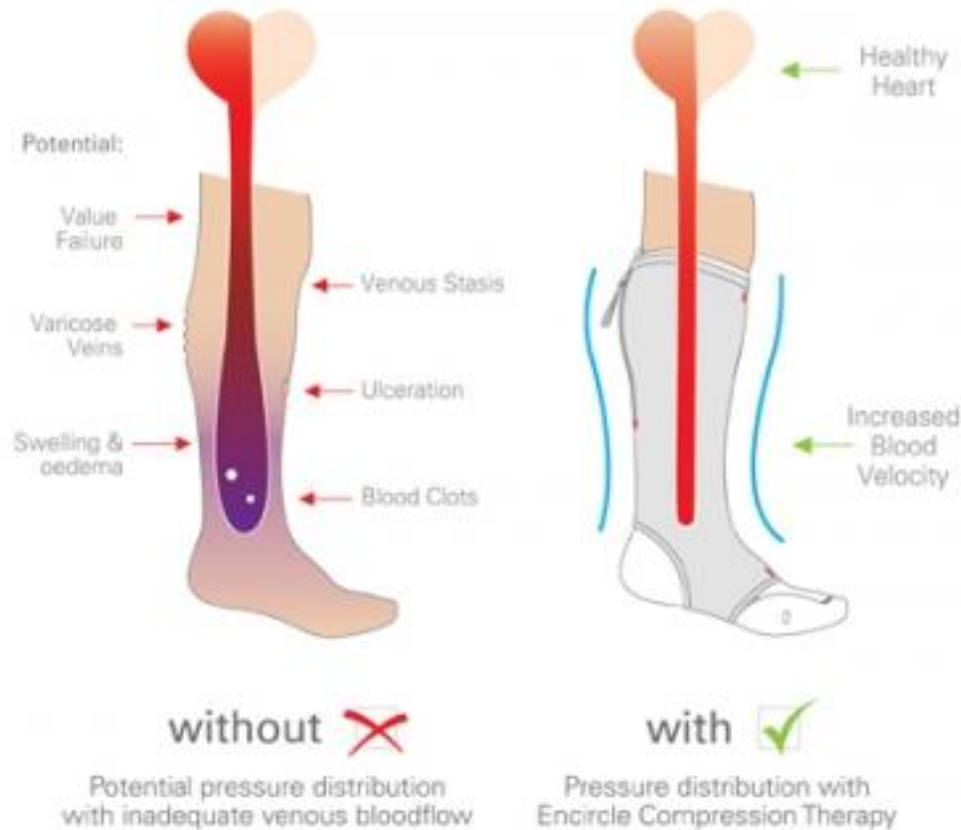Management Strategy

- Ulcer Care;
 - Tissue sampling.
 - Cleanse wound.
 - Appropriate dressing.
 - Regular evaluation.
- Venous evaluation;
 - Duplex and intervention as required.
 - May need to consider arterial assessment – ABPI.
- Compression Therapy;
 - Life-long in patients with venous ulcers.





Compression Therapy



Compression Therapy

- Graduated increase.
- Elastic stockings – Class I - III.
- Multi-Layer compression bandaging.
 - Base dressings, wool, crepe, additional elasticated layers.
- Be mindful of ABPI requirements.
 - 3-layer – ABPI >0.6 .
 - 4-layer – ABPIU >0.8 .



Compression Therapy

Compression-Hosiery Classification and Indications ^a		
Class	Pressure	Indications for Use
	8-15 mmHg (support) ^b	Tired/aching feet and legs, slight edema Spider veins, early varicose veins
1	14-17 mmHg ^c 15-20 mmHg ^b	Varicose veins, mild edema DVT prevention
2	18-24 mmHg ^c 20-30 mmHg ^b	Moderate varicose veins, mild edema Prevention of venous-ulcer recurrence
3	25-35 mmHg ^c 30-40 mmHg ^b	Severe varicose veins Prevention and treatment of venous ulcers Lymphedema Postphlebitic limb Chronic venous insufficiency

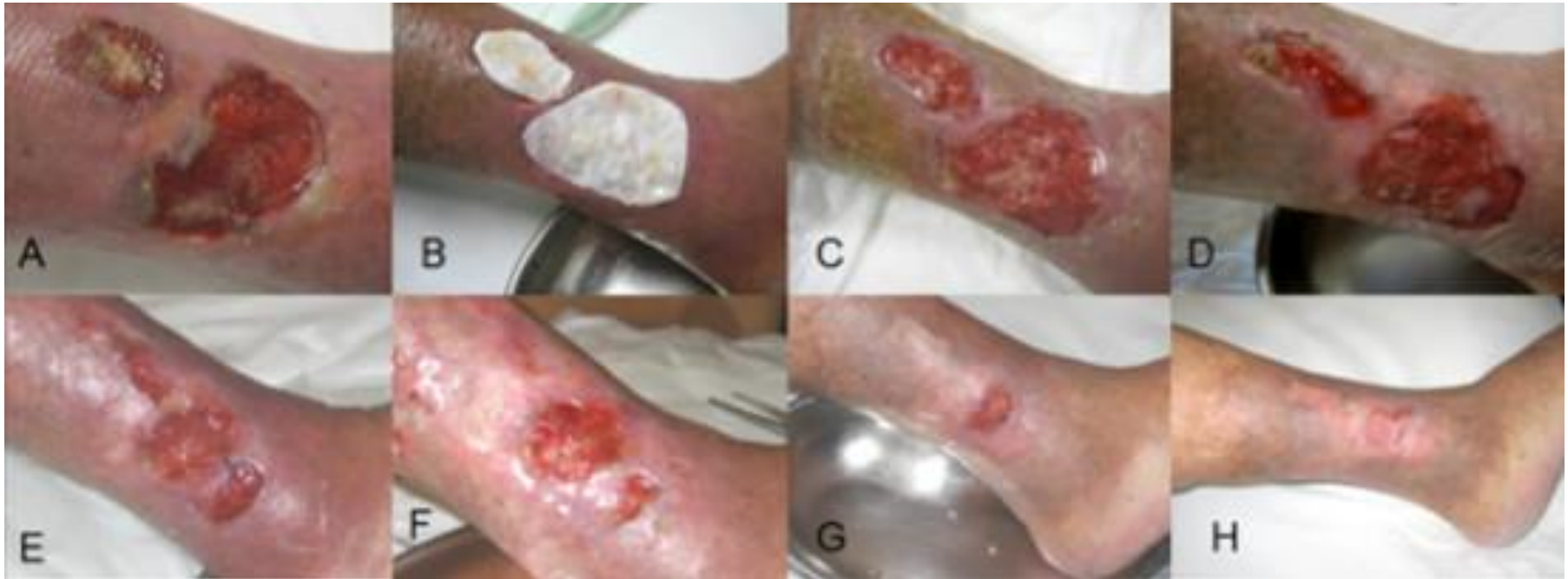^a Choice of type and level of compression is patient-specific. Patient considerations include arterial status and ability to tolerate and put on the stocking.




An Overview Of Compression Products For Venous Ulcers

Type	Trade Name	Company	Disposable	Reusable
Short stretch (Inelastic)	Comprilan Rosidal K LoPress Unna boot	Jobst Sammons Preston Hartmann Conco multiple	X	X X X
Long stretch (elastic)	SurePress Setopress	Convatec Sammons Preston		X X
Multilayer	Dufore 4 layer DeWrap System 3 Layer FourFlex 4-Layer Profore 4 layer	Derma Sciences DeRoyal Medline Smith & Nephew	X X X X	
Multilayer light	Profore Light (3 layer) Coban 2 Layer Lite	Smith & Nephew 3M	X X	
High elastic	ACE Elastic bandages Coban self adhesive Self adhesive	ACE Multiple 3M Multiple	X X	X X





Important Literature



Lancet. 2004 Jun 5;363(9424):1854-9.

Comparison of surgery and compression with compression alone in chronic venous ulceration (ESCHAR study): randomised controlled trial.

Barwell JR¹, Davies CE, Deacon J, Harvey K, Minor J, Sassano A, Taylor M, Usher J, Wakely C, Earnshaw JJ, Heather BP, Mitchell DC, Whyman MR, Poskitt KR.

+ Author information

Abstract

BACKGROUND: Chronic venous leg ulceration can be managed by compression treatment, elevation of the leg, and exercise. The addition of ablative superficial venous surgery to this strategy has not been shown to affect ulcer healing, but does reduce ulcer recurrence. We aimed to assess healing and recurrence rates after treatment with compression with or without surgery in people with leg ulceration.

METHODS: We did venous duplex imaging of ulcerated or recently healed legs in 500 consecutive patients from three centres. We randomly allocated those with isolated superficial venous reflux and mixed superficial and deep reflux either compression treatment alone or in combination with superficial venous surgery. Compression consisted of multilayer compression bandaging every week until healing then class 2 below-knee stockings. Primary endpoints were 24-week healing rates and 12-month recurrence rates. Analysis was by intention to treat.

FINDINGS: 40 patients were lost to follow-up and were censored. Overall 24-week healing rates were similar in the compression and surgery and compression alone groups (65% vs 65%, hazard 0.84 [95% CI 0.77 to 1.24]; $p=0.85$) but 12-month ulcer recurrence rates were significantly reduced in the compression and surgery group (12% vs 28%, hazard -2.76 [95% CI -1.78 to -4.27]; $p<0.0001$). Adverse events were minimal and about equal in each group.

INTERPRETATION: Surgical correction of superficial venous reflux reduces 12-month ulcer recurrence. Most patients with chronic venous ulceration will benefit from the addition of simple venous surgery.



Lancet. 2004 Jun 5;363(9424):1854-9.

Comparison of surgery and compression with compression alone in chronic venous ulceration (ESCHAR study): randomised controlled trial.

Barwell JR¹, Davies CE, Deacon J, Harvey K, Minor J, Sassano A, Taylor M, Usher J, Wakely C, Earnshaw JJ, Heather BP, Mitchell DC, Whyman MR, Poskitt KR.



Ab:

BA:

exe
doe
with

ME:

cen
con
con
hea

FIN:

con
moi
[95'

**Improvements in time to
ulcer recurrence but no
actual healing benefit**

but
or

r

12-
76

INTERPRETATION: Surgical correction of superficial venous reflux reduces 12-month ulcer recurrence. Most patients with chronic venous ulceration will benefit from the addition of simple venous surgery.



[Br J Surg.](#) 2005 Mar;92(3):291-7.

Randomized clinical trial of compression plus surgery versus compression alone in chronic venous ulceration (ESCHAR study)--haemodynamic and anatomical changes.

[Gohel MS](#)¹, [Barwell JR](#), [Earnshaw JJ](#), [Heather BP](#), [Mitchell DC](#), [Whyman MR](#), [Poskitt KR](#).

Author information

Abstract

BACKGROUND: The aim of this study was to evaluate the anatomical and haemodynamic effects of superficial venous surgery and compression on legs with chronic venous ulceration.

METHODS: Legs with open or recently healed ulceration and saphenous reflux were treated with multilayer compression bandaging or superficial venous surgery plus compression as part of a clinical trial. Venous duplex imaging was performed before treatment and at 1 year. Legs were stratified before surgery as having no deep reflux, segmental deep reflux or total deep reflux. Venous refill times (VRTs) were calculated before treatment and at 1 year using photoplethysmography, with and without a narrow below-knee cuff inflated to 80 mmHg.

RESULTS: Of 214 legs investigated, 112 were treated with compression and 102 with compression plus surgery. Saphenous surgery abolished deep reflux in ten of 22 legs with segmental deep reflux and three of 17 with total deep reflux. Overall median (range) VRT increased from 10 (3-48) to 15 (4-48) s 1 year after surgery ($P < 0.001$). Preoperative change in VRT on application of a below-knee tourniquet correlated with actual change in VRT following surgery.

CONCLUSION: Superficial venous surgery resulted in a significant haemodynamic benefit for legs with venous ulceration despite co-existent deep reflux; residual saphenous reflux was common.

Copyright (c) 2005 British Journal of Surgery Society Ltd.



Ann Vasc Surg. 2014 Oct;28(7):1744-50. doi: 10.1016/j.avsg.2014.05.005. Epub 2014 Jun 6.

The incidence and outcome of endothermal heat-induced thrombosis after endovenous laser ablation.

Kane K¹, Fisher T¹, Bennett M¹, Shutze W Jr², Hicks T¹, Grimsley B¹, Gable D¹, Pearl G¹, Smith B¹, Shutze W Sr¹.

Author information

Abstract

BACKGROUND: Endovenous laser ablation (EVLA) of the saphenous vein has become one of the preferred treatments for treating saphenous vein reflux that has resulted in symptomatic lower extremity venous insufficiency or varicose veins. This procedure was noted during initial reports to have a low incidence of postoperative thrombosis of the femoral or popliteal vein adjacent to the treated great saphenous vein (GSV) or small saphenous vein (SSV). Later clinical experience suggested that the actual incidence of this event is higher and it was subsequently termed endothermal heat-induced thrombosis (EHIT).

METHODS: We reviewed the office records and the pre- and post-treatment ultrasounds of patients undergoing EVLA in our office from 2005 to 2010 to determine the frequency of EHIT in patients we had treated and then graded them according to a previously published classification.

RESULTS: There were 528 veins treated in 192 men and 336 women. The clinical, etiology, anatomy, pathophysiology (CEAP) class for these patients was 1 (0), 2 (291), 3 (65), 4 (104), 5 (26), and 6 (40), respectively. The GSV was treated in 496 patients, the SSV in 22, and both were treated in 10 patients. EHIT occurred in 29 of the legs treated for an incidence of 5.1%. The EHIT in the femoral vein were of level 3 (3), 4 (7), 5 (12), and 6 (3), respectively. Two patients developed EHIT in the popliteal vein after EVLA of the SSV. Treatment for the EHIT consisted of observation (13), anticoagulation (9), antiplatelet therapy (2), and nonsteroidal anti-inflammatory agents (1). Duration of therapy was usually 1 week, but 7 patients were treated for periods ranging from 1 to 7 weeks. No pulmonary emboli occurred in any of these patients. The EHIT resolved completely in all patients.

CONCLUSIONS: EHIT after EVLA occurs frequently and mainly consists of low-risk level 3, 4, and 5 deep vein thrombosis. The risk of pulmonary embolism is low and the EHIT typically resolves after 1 week. It can be treated with a short course of antiplatelet or anticoagulation therapy, although observation appears to be sufficient as well for lesser grades of EHIT.



Ann Vasc Surg. 2014 Oct;28(7):1744-50. doi: 10.1016/j.avsg.2014.05.005. Epub 2014 Jun 6.

The incidence and outcome of endothermal heat-induced thrombosis after endovenous laser ablation.

Kane K¹, Fisher T¹, Bennett M¹, Shutze W Jr², Hicks T¹, Grimsley B¹, Gable D¹, Pearl G¹, Smith B¹, Shutze W Sr¹.

Awareness of EHIT

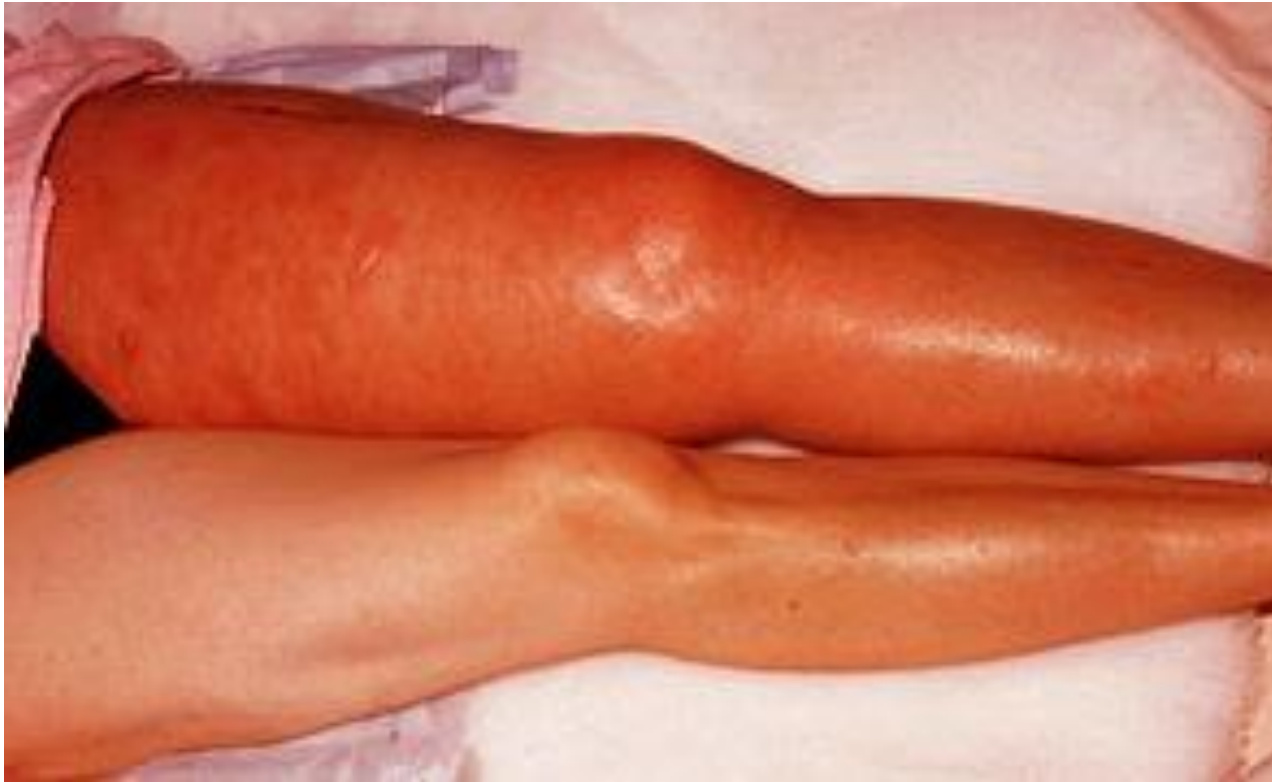Low risk of PE

Clinical observation suggested

The risk of pulmonary embolism is low and the EHIT typically resolves after 1 week. It can be treated with a short course of antiplatelet or anticoagulation therapy, although observation appears to be sufficient as well for lesser grades of EHIT.



Deep Venous Thrombosis



Definition

- Deep vein thrombosis (DVT) is the formation of a blood clot in one of the deep veins of the body, usually in the leg.
- DVT usually originates at the calf vein level and propagates proximally to involve popliteal, femoral or iliac system.
- 80 - 90% of pulmonary emboli originates here.



Epidemiology

- Very common with an incidence of 1.6 per 1000 persons per year.
- Incidence increases with age and remains very rare less than 18 years of age.



Aetiology

- Relates to Virchow's Triad;
 - Stasis of blood.
 - Vessel wall damage.
 - Hypercoagulability.



Clinical Presentation

- Calf pain or tenderness, or both.
- Swelling with pitting oedema or swelling below knee in distal deep vein thrombosis and up to groin in proximal deep vein thrombosis.
- Increased skin temperature.
- Superficial venous dilatation.
- Cyanosis can occur with severe obstruction.



Investigation

- Pro-thrombotic haematological work-up.
- Duplex ultrasound.
- Plethysmography.
- CT /MRI imaging.
- Pulmonary evaluation.

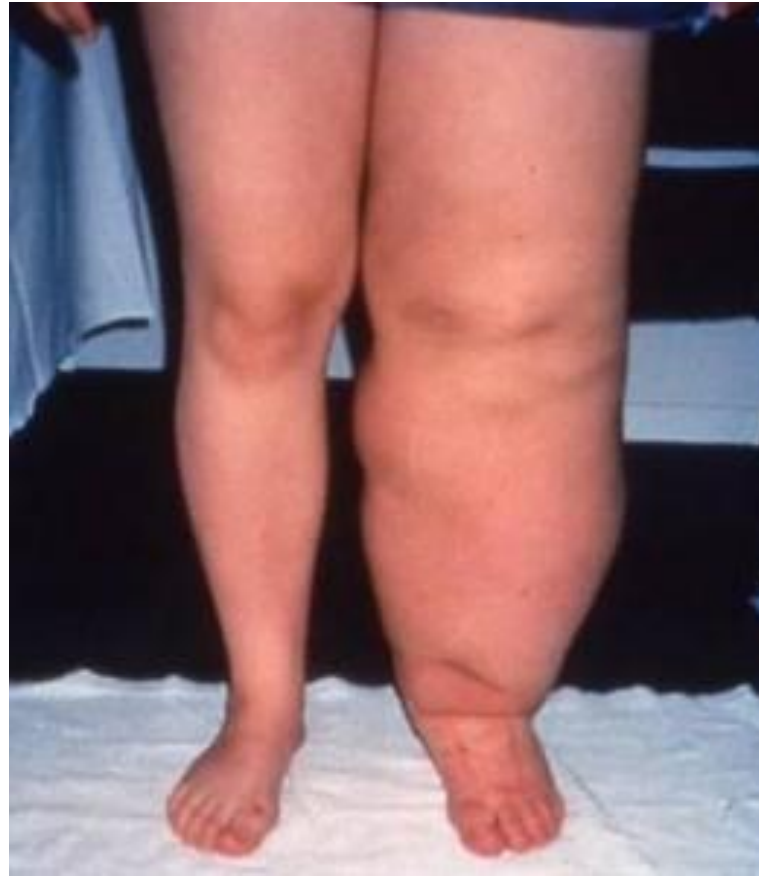

Treatment

- Risk factor evaluation.
- Elevation.
- Mobilise as tolerated.
- Anticoagulation.
- Endovascular thrombolysis.
- Surgical thrombectomy.



Lymphoedema



Definition

- Progressive, chronic and debilitating swelling that can affect any part of the body, most commonly the limbs leading to;
 - Distortion in shape and size.
 - Reduction of mobility.
 - Impaired function.



Types

- Primary:
 - Congenital Lymphedema:
 - A) Lymphedema Congenita.
 - B) Milroy's Disease (Hereditary).
 - Pubertal onset of oedema < 35 years age:
 - Lymphedema Praecox (Most common primary Lymphedema)
 - Middle age onset of oedema > 35 years age:
 - Lymphedema tarda (associated with injury).



Types

- Secondary – Acquired Lymphatic Obstruction:
 - Tumour obstruction of Regional lymph nodes:
 - Prostate Cancer
 - Lymphoma
 - Surgical excision or radiation to regional nodes:
 - Breast Cancer with axillary node dissection
 - Infection of regional lymph nodes:
 - A) Filariasis (*Wuchereria bancrofti*).
 - B) Tuberculosis.



Epidemiology

- Primary Lymphoedema occurs 1 in 10,000.



Clinical Presentation

- Early oedema (protein-rich fluid accumulation):
 - Soft "puffy" extremity swelling.
 - Maximal increase in girth in first year.
 - Easily pits.
 - Responds to limb elevation and compression.
 - Involves distal extremity (e.g. dorsal foot).
- Late oedema (inflammatory fibrosis):
 - Woody, firm non-Pitting Oedema (Brawny Oedema).
 - Skin thickened and hyperkeratotic.
 - Refractory to limb elevation and compression.



Investigation

- Duplex Ultrasound.
- Lymphangioscintigraphy.
- CT / MRI imaging.



Treatment

- General measures and education.
- Compression therapies;
 - Manual lymphatic drainage.
 - Graduated elastic compression.
 - Intermittent pneumatic compression.
 - Complex decongestive physiotherapy.
 - Thermal treatment.
- Prevention of infection.
- Benzopyrones / diuretics.



Surgical Treatment

- Excision of hypertrophic fibrotic subcutaneous tissue:
 - Indicated for elephantiasis.
- Types of procedures:
 - Charles Operation.
 - Kondoleon Procedure.
- Lymphatic pedicle transfer:
 - Supplies alternative lymph drainage.
 - No proven efficacy.
- Microvascular bypass of obstructed lymph channels:
 - Experimental.

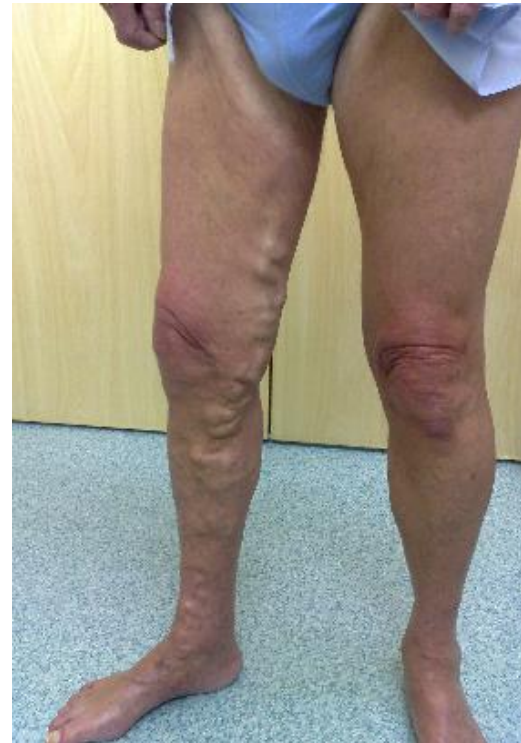

Cases



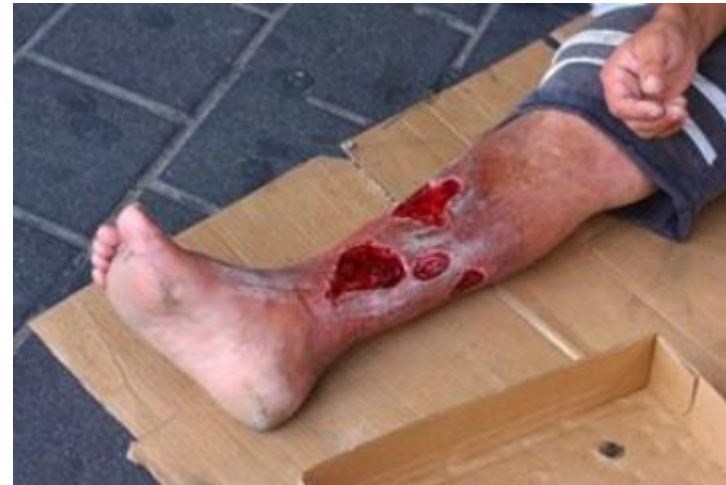Case 1

- 54 year old male patient;
 - Lower extremity ache and itch.
 - Otherwise well.



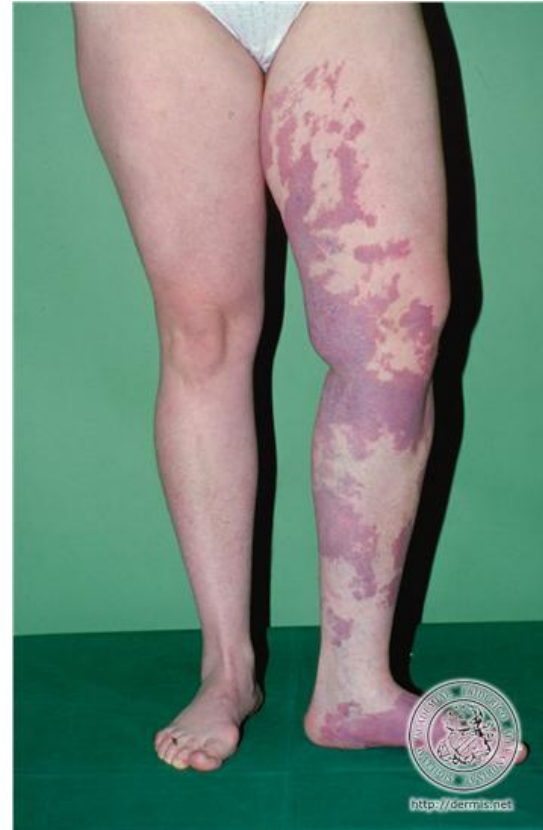Case 2

- 67 year old male;
 - 3 year history of deteriorating venous ulcer.
 - Cardiac history.
 - Smoker.
 - Ramipril, GTN, Nicorandil.



Case 3

- 19 year old female;
 - Left lower limb varicose veins.
 - Otherwise well.



Questions

